

# American Board of Family Medicine



IN-TRAINING EXAMINATION

TIME-4 HOURS

1. Which one of the following classes of medications for the treatment of diabetes mellitus is most likely to lead to weight loss?
  - A) GLP-1 receptor agonists such as exenatide (Byetta)
  - B) Meglitinides such as repaglinide (Prandin)
  - C) Sulfonylureas such as glipizide (Glucotrol)
  - D) Thiazolidinediones such as pioglitazone (Actos)
  - E) Insulin
  
2. The strategy that will identify the highest percentage of previously unrecognized cases of chronic hepatitis C is to screen which one of the following?
  - A) All sexually active men and women between the ages of 18 and 29
  - B) Everyone born between 1945 and 1965
  - C) Everyone who had a blood transfusion or organ transplant before 1992
  - D) Everyone who has ever used intravenous drugs
  - E) All men who have sex with men
  
3. A school nurse calls you for recommendations about a healthy 6-year-old female who was found to have head lice yesterday and was treated with permethrin 1% shampoo last night. The nurse reports that on examination today the child appeared well, weighed 30 kg (66 lb), and had 6 nits on her scalp.

In addition to home eradication measures and regular nit combing, you recommend which one of the following for this child?

- A) Oral ivermectin (Stromectol) and return to class today
  - B) Topical lindane and return to class today
  - C) Topical benzyl alcohol (Ulesfia) and return to class as soon as she is nit free
  - D) Return to class today and retreatment with permethrin 1% shampoo in 6 days
  - E) Retreatment with permethrin 1% shampoo in 6 days and return to class as soon as she is nit free
  
4. An 82-year-old male nursing home resident is sent to the emergency department with crampy lower abdominal pain and bloody diarrhea. On examination he has mild abdominal tenderness and slightly decreased bowel sounds. He has a previous history of vascular dementia, peripheral artery disease, hypertension, and hyperlipidemia. On examination he is afebrile, and a nasogastric aspirate is negative for evidence of bleeding.

Which one of the following is the most likely cause of this patient's bleeding?

- A) Peptic ulcer disease
- B) Ischemic colitis
- C) Diverticular bleeding
- D) Angiodysplasia
- E) Infectious colitis

5. Which one of the following screening tests has the greatest potential for overdiagnosis?

- A) Fecal occult blood testing
- B) Papanicolaou testing
- C) Prostate-specific antigen
- D) Mammography
- E) Low-dose CT to detect lung cancer

6. A 32-year-old female has recently started a regular running program to try to lose weight. Her BMI is 29.3 kg/m<sup>2</sup>. She presents to your office with a complaint of anterior knee pain that is worse on the right, with no history of an acute injury to her knee. She is not sure exactly when the pain began. On examination the patient has normal range of motion, no pain with palpation, and no effusion. Crepitus and lateral patellar tracking are noted in both knees, somewhat greater on the right.

Which one of the following is the most appropriate treatment for her condition?

- A) Patellar taping
- B) Reducing her running distance, and physical therapy
- C) Glucosamine and chondroitin
- D) Intra-articular corticosteroid injection
- E) Knee arthroscopy

7. A healthy 83-year-old female presents for an annual Medicare visit. Her blood pressure is 165/95 mm Hg on initial evaluation today and 160/92 mm Hg on repeat measurement. She has no health complaints.

The JNC 8 panel recommends which one of the following as the goal blood pressure for this patient?

- A) < 135/85 mm Hg
- B) < 140/90 mm Hg
- C) < 150/90 mm Hg
- D) < 160/90 mm Hg
- E) < 160/100 mm Hg

8. A 55-year-old male is found to be in cardiac arrest. When the EMTs arrive they note ventricular fibrillation on the monitor. The patient began an antibiotic 3 days ago for a mild case of community-acquired pneumonia.

Which one of the following antibiotics is most commonly associated with this scenario?

- A) Doxycycline
- B) Amoxicillin
- C) Cefuroxime (Ceftin)
- D) Azithromycin (Zithromax)

9. A 6-year-old male is brought to an urgent care center with a 48-hour history of left hip pain. He is noted to have a significant limp, but will walk. His father reports that the child prefers to lie on his back with his bent left knee out to the side. He is afebrile and well appearing, with an erythrocyte sedimentation rate of 10 mm/hr (N 3–13), a peripheral WBC count of 7000/mm<sup>3</sup> (N 5000–10,000), and a C-reactive protein level of 6 mg/L (N < 10). Radiographs of the left hip and knee are unremarkable.

Which one of the following would be most appropriate at this time?

- A) Ibuprofen
  - B) Acetaminophen/codeine
  - C) Vancomycin
  - D) Physical therapy referral
  - E) Urgent orthopedic consultation
10. Supraventricular tachycardia may require treatment both acutely and over the long term. Which one of the following medications is useful for both of these purposes?
- A) Adenosine (Adenocard)
  - B) Amiodarone (Cordarone)
  - C) Esmolol (Brevibloc)
  - D) Procainamide
  - E) Verapamil (Calan, Verelan)
11. A 16-year-old female is brought to your office by her mother, who is concerned that her daughter has seemed tired lately. The patient denies any specific health concerns or recent illnesses. She is taking an oral contraceptive and reports that her menstrual bleeding is light in flow. Recent laboratory findings include a TSH level of 1.44  $\mu$ U/mL (N 0.5–5.0), a hematocrit level of 38% (N 36–46), a mean corpuscular volume of 71  $\mu$ m<sup>3</sup> (N 78–102), an RBC count of 5.7 million/mm<sup>3</sup> (N 4.10–5.10), and ovalocytes on a peripheral smear.

Which one of the following is most likely to explain this patient's initial laboratory abnormalities and lead to a diagnosis?

- A) A vitamin B<sub>12</sub> level
- B) A ferritin level
- C) A free T<sub>4</sub> level
- D) Hemoglobin electrophoresis
- E) A fluorescent spot test

12. An 80-year-old male is admitted to the hospital for pneumonia. He develops what the nurses describe to you as “sundowning” behavior that includes nighttime disorientation and some mild agitation. His wife says he is not like this at home. During morning rounds he is pleasant and answers questions appropriately except he forgets why he is in the hospital. His examination, including a neurologic examination, is normal except for crackles on chest auscultation consistent with the pneumonia. He is not able to say the days of the week backwards.

Which one of the following is most likely in this patient?

- A) Alzheimer’s disease
  - B) Delirium
  - C) Vascular dementia
  - D) Encephalitis
  - E) Stroke
13. A 40-year-old female is concerned that she may have amyotrophic lateral sclerosis (ALS). Her paternal uncle died in his forties of this disease and she has visited multiple Internet sites that have exacerbated her fears.

Which one of the following findings on examination would be considered a clinical manifestation of ALS?

- A) A bull’s-eye rash
  - B) Paresthesias
  - C) Pseudoclaudication
  - D) Asymmetric leg weakness
  - E) Charcot joint
14. A 25-year-old male presents with pleuritic chest pain. He has not had a fever or symptoms of a respiratory infection. He has no risk factors for thromboembolism, and no past medical or family history of thromboembolism. His vital signs and examination are normal, including clear lungs on auscultation and no chest wall tenderness. Laboratory findings include a normal CBC and a normal D-dimer level. A chest radiograph is also normal.

Which one of the following is the most appropriate next step in this patient’s management?

- A) An NSAID
- B) An anticoagulant pending further imaging
- C) C-reactive protein and antinuclear antibody levels, and corticosteroids
- D) A rib belt

15. A 65-year-old white female with terminal cancer and severe hepatic dysfunction has musculoskeletal and neuropathic pain at the end of life. Which one of the following medications should not be used in this patient because of her hepatic dysfunction?
- A) Fentanyl
  - B) Hydromorphone (Dilaudid)
  - C) Methadone
  - D) Morphine
  - E) Oxycodone (OxyContin)

16. A 55-year-old female with hypertension sees you for a routine follow-up visit. A physical examination is normal except for a BMI of 34.0 kg/m<sup>2</sup>. Laboratory findings are notable for an ALT (SGPT) of 53 U/L (N 7–35), and an AST (SGOT) of 28 U/L (N 10–34). She had a similar elevation a month ago when she was seen in the emergency department. Her comprehensive metabolic panel is otherwise normal, and a CBC is also normal. She has had negative hepatitis B surface antigen and hepatitis C antibody testing in the past. She does not drink alcohol or take medications that affect liver function.

Which one of the following is the most appropriate test for evaluating this patient?

- A) Anti-smooth muscle antibody
  - B) Ceruloplasmin
  - C) Hepatitis D antibody
  - D) Iron studies
  - E) A liver biopsy
17. Pregnant women who empty cat litter boxes are at increased risk for which one of the following?
- A) Toxoplasmosis
  - B) *Toxocara mystax* (*Toxocara cati*) infection
  - C) Chagas disease
  - D) Cysticercosis
  - E) Aspergillosis
18. Which one of the following has been shown to result from the use of continuous prophylactic antibiotics in patients with moderate COPD?
- A) A clinically significant reduction in COPD exacerbations
  - B) A clinically significant improvement in quality-of-life scores
  - C) A demonstrable decrease in the number of resistant organisms in the sputum
  - D) The development of conduction defects, including prolonged QT intervals
  - E) An increased incidence of tinnitus

19. Which one of the following services must be covered by any insurance purchased through the insurance marketplace, as long as the patient sees an in-network provider?
- A) Preventive dental care
  - B) Annual eye examinations by an optometrist or ophthalmologist
  - C) Colorectal cancer screening
  - D) Travel immunizations for work-related travel
  - E) Bariatric surgery for morbidly obese patients

20. A 65-year-old male has severe liver cirrhosis from a combination of hepatitis C infection and alcohol abuse. He previously underwent a transjugular intrahepatic portosystemic shunt (TIPS) procedure.

While the TIPS procedure reduces the likelihood of most complications of cirrhosis, it may increase the risk for which one of the following?

- A) Anasarca
  - B) Ascites
  - C) Hepatic encephalopathy
  - D) Upper gastrointestinal bleeding from esophageal varices
  - E) Upper gastrointestinal bleeding from portal hypertensive gastropathy
21. A 77-year-old white male tells you he has had urinary incontinence for more than a year. The incontinence occurs with sudden urgency. No association with coughing or positional change has been noted, and there is no history of fever or dysuria. He underwent transurethral resection of the prostate (TURP) for benign prostatic hyperplasia a year ago, and he says his urinary stream has improved. A rectal examination reveals a smoothly enlarged prostate without nodularity, and normal sphincter tone. No residual urine is found with post-void catheterization.

Which one of the following is the most likely cause of this patient's incontinence?

- A) Detrusor instability
- B) Urinary tract infection
- C) Overflow
- D) Fecal impaction
- E) Recurrent bladder outlet obstruction

22. A 45-year-old female with a BMI of 50.0 kg/m<sup>2</sup> comes to your office to discuss treatment of her chronically elevated fasting glucose levels. Recent test results include a hemoglobin A<sub>1c</sub> of 6.0%. In the past she was not able to tolerate metformin (Glucophage) and would like to try another medication to reduce her risk of developing diabetes mellitus.

Which one of the following medications would be most appropriate for this patient?

- A) Acarbose (Precose)
- B) Bromocriptine (Parlodel)
- C) Canagliflozin (Invokana)
- D) Glipizide (Glucotrol)
- E) Sitagliptin (Januvia)

23. A 33-year-old patient with allergic rhinitis tells you he feels drowsy when taking diphenhydramine (Benadryl) and asks if there is an alternative that will cause less sedation. You tell him that most second-generation antihistamines have a better adverse effect profile and cause less sedation than first-generation antihistamines.

Which one of the following second-generation antihistamines would you advise the patient to avoid, however, because it is known to cause sedation?

- A) Cetirizine (Zyrtec)
- B) Desloratadine (Clarinex)
- C) Fexofenadine (Allegra)
- D) Levocetirizine (Xyzal)
- E) Loratadine (Claritin)

24. The mother of a 16-year-old male calls to report that her son has a severe sore throat and has been running a fever of 102°F. As you question the mother further, which one of the following would be most specific for peritonsillar abscess?

- A) A 1-day duration of illness
- B) Ear pain
- C) Difficulty opening his mouth
- D) Hoarseness
- E) Pain with swallowing



25. A 14-year-old goalkeeper dives for a save during a soccer game and strikes her head on the goalpost. She does not lose consciousness but develops a headache and is removed by the coach for the remainder of the game. She becomes nauseated and has balance problems over the next several hours but can clearly recall the event. She comes to your clinic the following day. Her school requires baseline neurocognitive testing prior to all sports participation each year and you have a copy of this year's results.

Which one of the following would be the most appropriate recommendation at this time?

- A) CT of the head
- B) Return to practice when her symptoms are relieved by medication
- C) Neurocognitive testing at this visit
- D) Physical and cognitive rest
- E) The use of protective headgear for the remainder of the season

26. A 70-year-old male has a smoking history of > 30 pack-years. He quit 10 years ago.

Which one of the following is recommended by the U.S. Preventive Services Task Force with regard to lung cancer screening for this patient?

- A) Low-dose noncontrast chest CT one time only
- B) A standard chest radiograph and sputum cytology one time only
- C) Low-dose noncontrast chest CT annually
- D) Low-dose noncontrast chest CT every 3 years
- E) No screening

27. A 25-year-old primigravida at 33 weeks gestation presents to the labor suite with a complaint of painful uterine contractions every 3 minutes for the last 2 hours. A fetal monitor confirms the contraction pattern, and the fetal heart rate pattern is category 1. A fetal fibronectin test is ordered.

Thirty minutes later the contractions have stopped, but results of the fetal fibronectin test are positive. A speculum examination shows no indication of ruptured membranes. The cervix is closed and thick to palpation.

The positive result on this patient's fetal fibronectin test

- A) has a low positive predictive value for preterm delivery
- B) indicates a high likelihood of delivery before term
- C) indicates a high likelihood of delivery within the next week
- D) indicates occult rupture of the membranes
- E) is diagnostic for preterm labor

28. The rash associated with erythema infectiosum (fifth disease) is characterized by which one of the following?
- A) Small red papules with central umbilication
  - B) Annular patches with raised borders and central clearing
  - C) Pink pustules that form a thick yellow crust
  - D) An erythematous “slapped cheek” facial rash
  - E) A symmetrical rash in a Christmas tree pattern
29. A 64-year-old male with nonvalvular atrial fibrillation has received anticoagulation therapy with warfarin (Coumadin) for the past 3 years but it has been difficult to maintain his INR in the therapeutic range. He has been afraid to transition to one of the newer oral anticoagulants because of the lack of a reversal medication should he develop life-threatening bleeding.
- Which one of the following now has a reversal agent?
- A) Apixaban (Eliquis)
  - B) Dabigatran (Pradaxa)
  - C) Edoxaban (Savaysa)
  - D) Rivaroxaban (Xarelto)
30. Both the American Academy of Family Physicians and the American College of Obstetricians and Gynecologists recommend that non-medically indicated (elective) inductions of labor or cesarean deliveries should be scheduled after what gestational age?
- A) 37 weeks, 0 days
  - B) 39 weeks, 0 days
  - C) 40 weeks, 0 days
  - D) 41 weeks, 0 days
  - E) 42 weeks, 0 days
31. Which one of the following is effective in preventing seizures associated with alcohol withdrawal syndrome?
- A) Carbamazepine (Tegretol)
  - B) Chlordiazepoxide
  - C) Clonidine (Catapres)
  - D) Gabapentin (Neurontin)
  - E) Phenytoin

32. A 66-year-old female with a history of shortness of breath returns to your office to review her pulmonary function test results. Her FEV<sub>1</sub>/FVC ratio is 76%. You calculate that her FVC is below the normal range for an adult. Her DLCO is also low.

Which one of the following is most consistent with her pulmonary function test results?

- A) COPD
  - B) Asthma
  - C) Idiopathic pulmonary fibrosis
  - D) Chronic pulmonary emboli
  - E) Morbid obesity
33. Which one of the following is the recommended initial treatment for allergic rhinitis in a patient whose symptoms are affecting his quality of life?
- A) An oral corticosteroid
  - B) An intranasal corticosteroid
  - C) An intranasal antihistamine
  - D) Subcutaneous immunotherapy injection
  - E) Sublingual immunotherapy

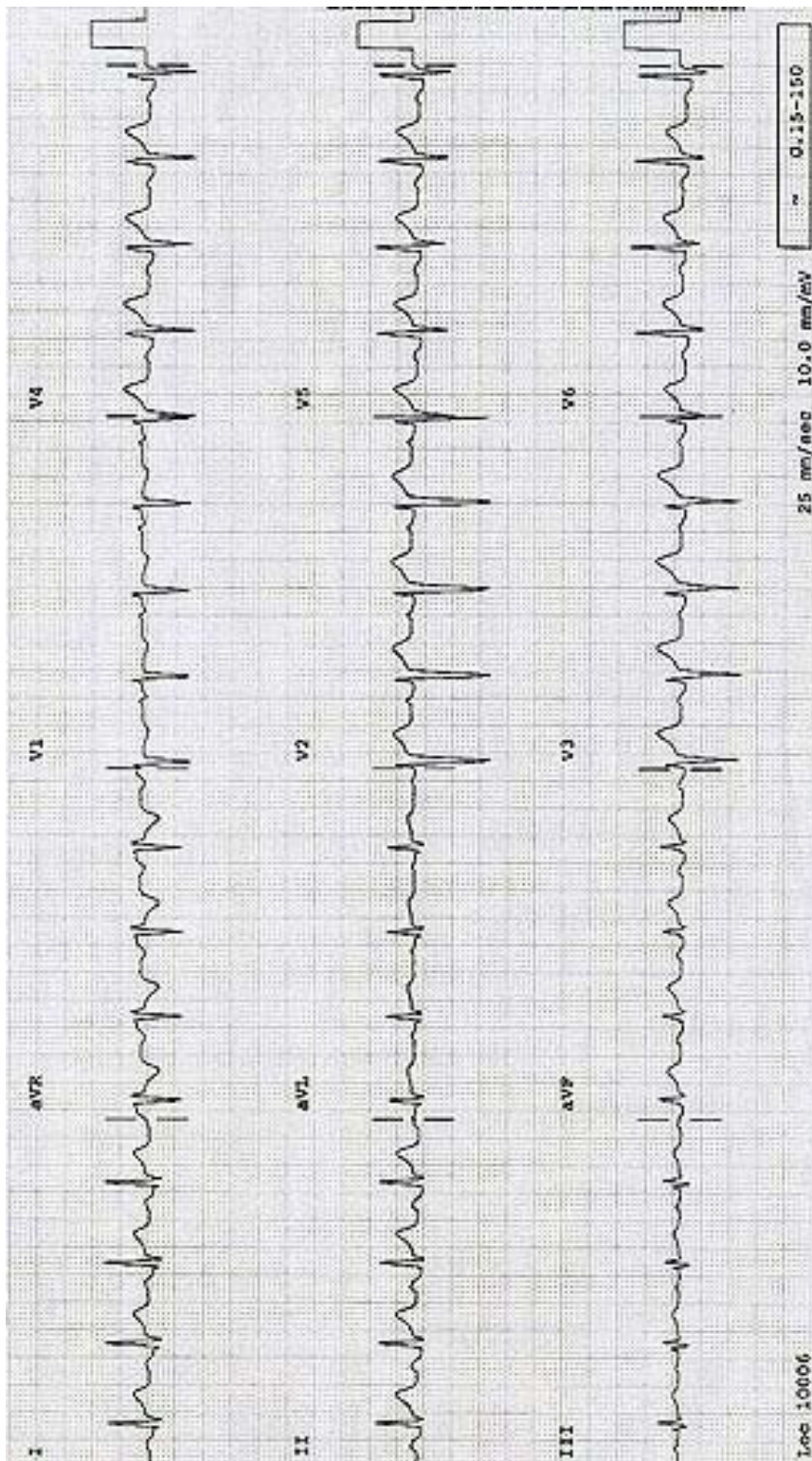
34. A 32-year-old male presents with an acute onset of chest pain. His EKG is shown on the page at right.

Which one of the following agents would be most appropriate to relieve this patient's chest pain?

- A) Hydrocodone (Lortab)
  - B) Indomethacin (Indocin)
  - C) Nitroglycerin
  - D) Omeprazole (Prilosec)
  - E) Oxygen
35. A 40-year-old male presents to the emergency department with a fever and acute, severe abdominal pain. A complete history and careful physical examination fail to localize the source of his pain, and basic blood and urine tests also prove to be nondiagnostic. His pain is diffuse, and you are concerned about a potentially serious pathology.

Which one of the following would be most appropriate to order next?

- A) Plain radiographs of the abdomen
- B) An upper gastrointestinal series with small-bowel follow-through
- C) Ultrasonography of the abdomen
- D) CT of the abdomen and pelvis
- E) MRI of the abdomen



Item #34

36. A 46-year-old male consults you because of chronic, moderate, nonradiating low back pain. The pain had a gradual onset and is partially relieved by rest; ibuprofen, 600 mg as needed; duloxetine (Cymbalta), 60 mg daily; and gabapentin (Neurontin), 300 mg 3 times/day. He denies weakness, changes in urination, or changes in sensation. His physical examination is notable for mild tenderness over the lumbar paraspinal muscles. A recent MRI of his lumbosacral spine showed mild degenerative disc disease.

Which one of the following would you recommend as most likely to have long-term benefit?

- A) A walking program
  - B) A trial of chiropractic care
  - C) A series of epidural corticosteroid injections
  - D) A transcutaneous electrical nerve stimulation (TENS) unit
  - E) A spinal cord stimulator
37. A 30-year-old female with hyperthyroidism is treated with methimazole (Tapazole). Which one of the following is a potential adverse reaction?

- A) Agranulocytosis
- B) Aplastic anemia
- C) Thrombocytopenia
- D) Ototoxicity
- E) Renal toxicity

38. A 42-year-old female visits your office. She has alcohol use disorder and wants to quit drinking. She recently went through inpatient detoxification and is attending Alcoholics Anonymous meetings and counseling. She continues to have strong cravings and is fearful of a relapse. Her medical history is notable for renal disease and osteopenia.

Which one of the following would be most appropriate for this patient?

- A) Acamprosate
  - B) Disulfiram (Antabuse)
  - C) Naltrexone (ReVia)
  - D) Bupropion (Wellbutrin)
39. Which one of the following antidepressants should be avoided in the elderly?
- A) Bupropion (Wellbutrin)
  - B) Sertraline (Zoloft)
  - C) Mirtazapine (Remeron)
  - D) Paroxetine (Paxil)
  - E) Venlafaxine

40. The American Academy of Pediatrics recommends administration of an autism-specific screening tool at which well child visits?
- A) 18 and 24 months
  - B) 2 and 3 years
  - C) 3 and 5 years
  - D) 5 and 10 years
  - E) 10 and 12 years

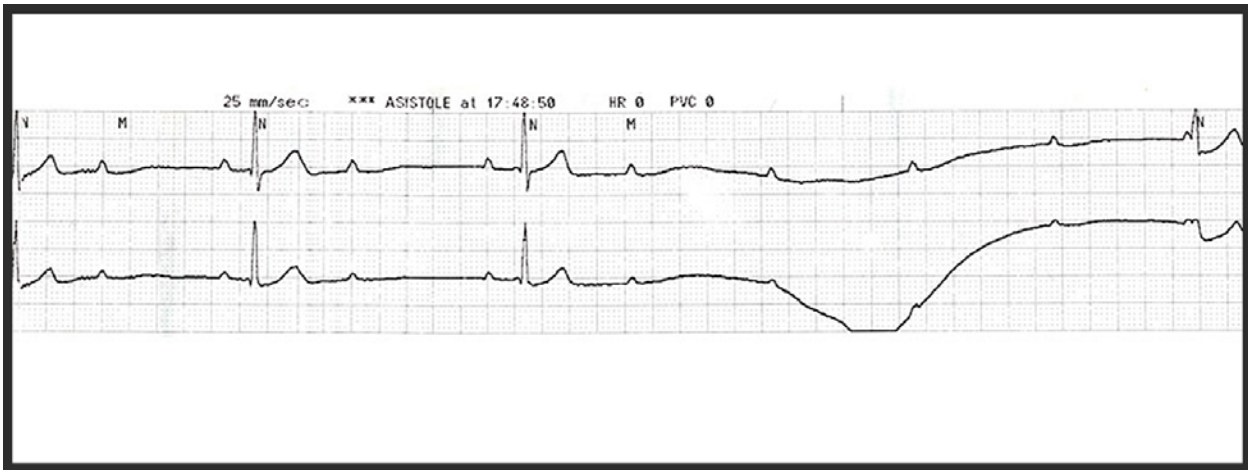
41. A 25-year-old female is concerned about contracting human papillomavirus (HPV) and cervical cancer because she has a new sexual partner who was recently treated for genital warts. She has not received any medical care in over 5 years. She reports a lifetime total of four sexual partners and denies any chronic medical problems, but is a smoker. Her maternal grandmother died of cervical cancer. Her chart indicates that she completed the HPV vaccination series. A physical examination is normal.

Which one of the following is the most appropriate screening test for this patient?

- A) Colposcopy
  - B) HPV DNA typing
  - C) HPV antibodies
  - D) A Papanicolaou (Pap) test and HPV cotesting
  - E) A Pap test with reflex high-risk HPV testing
42. A 56-year-old male is hospitalized for workup of a syncopal episode. He has a history of type 2 diabetes mellitus and dyslipidemia, which are well controlled with metformin (Glucophage) and atorvastatin (Lipitor). In addition, he takes a daily low-dose aspirin and a multivitamin. The cardiac examination reveals occasional skipped beats but the remainder of the physical examination is normal. While hospitalized he has another syncopal episode. His clinical examination and EKG post syncope are normal. A telemetry rhythm tracing captured during this syncopal episode is shown on the page at right.

Which one of the following is the most likely cause of his syncope?

- A) Atrial fibrillation
  - B) Mobitz type I second degree atrioventricular block
  - C) Mobitz type II second degree atrioventricular block
  - D) Third degree atrioventricular block
43. Which one of the following is the most common neurologic complication of Paget's disease of the bone?
- A) Headache
  - B) Facial palsy
  - C) Hearing loss
  - D) Spinal stenosis
  - E) Hydrocephalus



Item #42

44. A 4-year-old female slipped and fell off the edge of a dock but did not go underwater because her mother caught her by the hand and pulled her back. Since that time she has been upset and has not wanted to play, keeping her arm slightly bent and close to her side.

The physical examination supports your initial diagnosis. Which one of the following would be the best management?

- A) No immobilization, with follow-up in 24 hours
  - B) Placing the arm in a sling
  - C) Attempting reduction by hyperpronation
  - D) A long arm posterior splint
  - E) A figure-of-eight harness
45. A 30-year-old male is diagnosed with Lyme disease and is concerned because he read that this can lead to heart disease. Which one of the following is the most common cardiac problem associated with this disease?
- A) Endocarditis
  - B) Heart block
  - C) Pericardial effusion
  - D) Pulmonary edema
  - E) Valvular heart disease
46. An orthopedic surgeon contacts you about abnormal preoperative laboratory results for one of your patients. The patient is a 58-year-old male who takes acetaminophen and over-the-counter naproxen for pain but is otherwise healthy and has no symptoms.

Laboratory Findings

WBCs	3000/mm <sup>3</sup> (N 3000–11,600)
Hemoglobin	8.9 g/dL (N 13.0–18.0)
Hematocrit	26.9% (N 38.5–52.0)
Platelets	118,000/mm <sup>3</sup> (N 130,000–140,000)
Mean corpuscular volume	89 μm <sup>3</sup> (N 80–98)
Red cell distribution width	12.6% (N 11.0–14.5)
Serum vitamin B <sub>12</sub>	457 pg/mL (N 220–960)
Ferritin	258 μg/L (N 24–336)
Reticulocytes	1.5% (N 0.8–2.1)

Which one of the following is most consistent with these results?

- A) Folate deficiency
- B) Iron deficiency
- C) Hemolysis
- D) Acute blood loss
- E) Bone marrow suppression



47. A 35-year-old female has had a foul-smelling vaginal discharge for the past week since having sexual intercourse with a new male partner. It does not seem thicker than her usual discharge. She does not have any itching or pain with intercourse.

Which one of the following are you most likely to find on examination?

- A) Evidence of excoriation of the vulva
- B) Vulvar erythema
- C) Vaginal atrophy
- D) A vaginal pH of 4.0–4.5
- E) A vaginal pH >4.5

48. A 29-year-old female presents to your office for a routine prenatal visit at 30 weeks gestation. She received Tdap vaccine during her last pregnancy 3 years ago.

Which one of the following should she receive today?

- A) Live attenuated influenza vaccine
- B) MMR
- C) Tdap
- D) Varicella vaccine
- E) No vaccine

49. A 72-year-old female sees you for a preoperative evaluation prior to cataract surgery. Her history and physical examination are unremarkable, and she has no medical problems other than bilateral cataracts.

Which one of the following is recommended prior to surgery in this patient?

- A) An EKG only
- B) An EKG and chest radiography
- C) A CBC only
- D) A CBC and serum electrolytes
- E) No testing

50. A 74-year-old male who recently underwent lumbar laminectomy for spinal stenosis complains of pain in his right great toe. He is unable to ambulate due to the pain. His other chronic medical problems include hypertension and stage 4 chronic kidney disease. On examination he has erythema, edema, warmth, and tenderness over the right first metatarsal joint.

Which one of the following is the best initial treatment for his condition?

- A) Allopurinol (Zyloprim)
- B) Colchicine (Colcrys)
- C) Indomethacin
- D) Prednisone
- E) Probenecid

51. A 40-year-old male is brought to the emergency department with seizures and a change in his mental status. He is found to be severely hyponatremic with a serum sodium level of 112 mEq/L (N 135–145).

Initial management while evaluating this patient further should include which one of the following?

- A) Infusion of 0.45% saline
- B) Infusion of 3% saline
- C) Infusion of normal saline
- D) Fluid restriction
- E) Hemodialysis

52. An 82-year-old bedridden male develops a partial thickness skin loss ulcer (stage 2) over his right heel. He is noted to have a dry, intact eschar without erythema or fluctuance.

After gentle cleansing with saline, which one of the following is the most appropriate management of this wound?

- A) Additional cleansing with a chlorine-based (Dakin's) solution
- B) Additional cleansing with a povidone-iodine solution (Betadine)
- C) Application of a moist, nonadhesive bandage
- D) Application of a wet-to-dry dressing
- E) Sharp debridement of the dry eschar

53. Which one of the following has been consistently identified as the most common cause of medication-related adverse events across health care settings in the United States?

- A) Antibiotics
- B) Anticoagulants
- C) Chemotherapeutic agents
- D) Diabetic agents
- E) Opioids

54. A 63-year-old female complains of left shoulder pain and stiffness that have been increasing in severity for the last year. She works as a hotel housekeeper. On examination you note decreased passive and active range of motion of her left shoulder compared to the right. Both active and passive motion produce pain.

Which one of the following is the most likely diagnosis?

- A) Glenohumeral osteoarthritis
- B) Subdeltoid bursitis
- C) Adhesive capsulitis
- D) Partial rotator cuff tear
- E) Teres minor myositis

55. A 34-year-old female with no significant past medical history is being evaluated for acute abdominal pain. CT of the abdomen reveals a 3-cm right adrenal mass.

This lesion is most likely to be which one of the following?

- A) A benign adenoma
  - B) An adrenocortical carcinoma
  - C) A pheochromocytoma
  - D) A neuroblastoma
  - E) A metastatic lesion
56. Which one of the following is a risk factor for uncomplicated cystitis?
- A) Obesity
  - B) Low fluid intake
  - C) Frequent sexual intercourse
  - D) Use of hot tubs
  - E) Wearing synthetic underwear
57. A 65-year-old female sees you for a routine health maintenance visit. She has a newborn granddaughter that she is planning to watch a few days a week and asks if there are any vaccines that she can get that will help protect the health of her granddaughter. She has not received any vaccines other than yearly influenza vaccine in the past 20 years.

According to the Centers for Disease Control and Prevention, which one of the following would be recommended for her to protect her infant grandchild from illness?

- A) Meningococcal vaccine (Menactra)
  - B) 13-valent pneumococcal conjugate vaccine (Prevnar 13)
  - C) 23-valent pneumococcal polysaccharide vaccine (Pneumovax 23)
  - D) Tdap
  - E) Varicella vaccine
58. A 64-year-old female with a history of controlled hypertension reports that her older sister was recently hospitalized for a stroke. The patient feels well and has never had stroke symptoms. She requests your advice regarding carotid artery screening for stroke risk reduction.

Which one of the following would you recommend?

- A) Carotid artery ultrasonography only if she has two or more cardiovascular risk factors
- B) Carotid artery ultrasonography once between the ages of 65 and 75 if she is a former smoker
- C) Carotid artery ultrasonography once at age 65
- D) Carotid artery auscultation annually after age 65
- E) No screening for carotid artery disease

59. A 52-year-old female presents with a 5-day history of nasal congestion, facial pressure, heavy nasal discharge, and decreased sense of smell. She has not had a fever and says her symptoms have not started to improve. She is mildly tender over both maxillary sinuses. Even though you have reassured her that this is most likely a viral illness, she would like antibiotics because she is going on vacation in 2 days and she wants to be better for her trip.

Which one of the following strategies has been shown to improve the acceptance of symptomatic care only and reduce the use of antibiotics in this situation?

- A) Using medical terminology for the condition, such as *acute bronchitis* or *acute tracheitis*
  - B) Providing a “pocket” prescription with advice to fill it after a defined period without improvement
  - C) Ordering sinus radiographs
  - D) Referral to a specialist
60. A 19-year-old female sees you for evaluation of severe dysmenorrhea. She tells you she is not sexually active and has never had intercourse. A physical examination is unremarkable and you determine that a pelvic examination is not necessary.

Which one of the following is the treatment of choice for this patient?

- A) Acetaminophen
  - B) Hydrocodone
  - C) Medroxyprogesterone acetate (Depo-Provera)
  - D) An NSAID
  - E) An oral contraceptive
61. A 44-year-old male presents to the emergency department in the evening with facial, lip, and tongue edema that has been gradually progressing over the last few hours. He was started on lisinopril (Prinivil, Zestril) earlier today for mild hypertension. He does not have a rash or pruritus. He reports tightness in his throat and, although he is moving air well at this time, you do note some mild stridor.

Which one of the following is most likely to prevent the need for intubation?

- A) Epinephrine
- B) An antihistamine such as diphenhydramine (Benadryl)
- C) An angiotensin receptor blocker such as losartan (Cozaar)
- D) A bradykinin receptor antagonist such as icatibant (Firazyr)
- E) A corticosteroid such as methylprednisolone (Medrol)

62. A 62-year-old male is admitted to the hospital for urosepsis. His past medical history is significant only for hypertension. On examination he has a temperature of 36.5°C (97.7°F), a TSH level of 0.2 μU/mL (N 0.4–5.0), and a free T<sub>4</sub> level of 0.4 ng/dL (N 0.6–1.5).

Which one of the following is the most likely explanation for these findings?

- A) Pituitary adenoma
- B) Graves disease
- C) Subacute thyroiditis
- D) Subclinical hypothyroidism
- E) Euthyroid sick syndrome

63. A 56-year-old male with daily heartburn symptoms is found to have Barrett's esophagus on endoscopy. Biopsies do not show any evidence of dysplasia.

Which one of the following should be recommended for surveillance of this condition?

- A) Endoscopy every year
- B) Endoscopy every 3 years
- C) Endoscopy every 10 years
- D) A PET scan every 2 years
- E) No routine surveillance, with endoscopy only if symptoms worsen

64. A healthy 65-year-old female is noted to have a 1.5-cm thyroid nodule during a routine health maintenance visit. She has no history of radiation exposure or cancer, and no family history of endocrine cancers.

Which one of the following would be most appropriate at this point?

- A) A TSH level
- B) Antithyroid antibody
- C) A fine-needle aspiration biopsy
- D) Thyroid ultrasonography
- E) A thyroid radionuclide scan

65. A 40-year-old male develops a keloid 6 months after a laceration repair. Which one of the following is the most appropriate initial treatment to decrease the size of the keloid?

- A) Topical retinoids
- B) Topical corticosteroids
- C) Intralesional corticosteroid injections
- D) Surgical excision
- E) Mohs surgery

66. A 45-year-old male reports being held up at gunpoint while on vacation 3 months ago. Since that time he has had intrusive memories of the event, as well as nightmares. Further questioning reveals that he has been having dissociative reaction flashbacks and meets the criteria for posttraumatic stress disorder.

Which one of the following is the most appropriate pharmacotherapy for this patient?

- A) Clonazepam (Klonopin)
  - B) Clonidine (Catapres)
  - C) Mirtazapine (Remeron)
  - D) Sertraline (Zoloft)
  - E) Risperidone (Risperdal)
67. Which one of the following is more characteristic of Crohn's disease, as opposed to ulcerative colitis?
- A) Bloody diarrhea
  - B) Perianal manifestations
  - C) Involvement of the rectum
  - D) Proximal progression
  - E) Associated inflammatory arthropathies
68. A 75-year-old male has a past medical history significant for atrial fibrillation, ischemic cardiomyopathy, diabetes mellitus, and hyperlipidemia. He is admitted to the hospital with bronchiolitis obliterans organizing pneumonia (cryptogenic organizing pneumonia).

Which one of the medications he takes is the most likely cause of this problem?

- A) Amiodarone (Cordarone)
  - B) Carvedilol (Coreg)
  - C) Digoxin (Lanoxin)
  - D) Lisinopril (Prinivil, Zestril)
  - E) Pioglitazone (Actos)
69. A 4-year-old female is brought to your office with a limp that was first noted 2 days ago. There has been no known injury or recent illness. Her vital signs are normal. Observation of her gait reveals shortening of the stance phase to take weight off her left leg. The physical examination reveals an otherwise healthy female with no focal tenderness or pathology of her lower legs or abdomen.

Which one of the following would be most appropriate at this point?

- A) A CBC, erythrocyte sedimentation rate, and C-reactive protein level
- B) Plain radiographs of both lower extremities
- C) Ultrasonography of both hips
- D) MRI of the left lower extremity, including the hip
- E) A bone scan

70. A 26-year-old male who is in a monogamous sexual relationship with another male sees you for a routine health maintenance visit. He is employed in a grocery store, is in good health, and reports having the usual immunizations as a child.

Based on expert consensus, which one of the following would be most appropriate at this visit?

- A) Pre-exposure HIV prophylaxis
- B) Screening for STIs now and every 3 months
- C) Meningococcal vaccine
- D) Hepatitis B surface antigen (HBsAG) testing

71. A 65-year-old white female requests bone density screening because her mother had premenopausal osteoporosis. The patient has no previous history of fracture, and her past medical and family histories are otherwise unremarkable. She has not had a hysterectomy and is not taking any medications or supplements. Her dietary calcium intake is low. DXA shows T-scores of  $-1.8$  at the hip and  $-2.1$  at the spine. Her estimated 10-year risk of hip fracture is 1.3%. Serum TSH, calcium, and 25-hydroxyvitamin D levels are normal.

Which one of the following would be most appropriate at this time?

- A) An increase in dietary calcium to 1200 mg daily and starting vitamin D<sub>3</sub> (cholecalciferol) supplementation, 800 IU daily
- B) Alendronate (Fosamax), 70 mg orally once weekly for 5 years
- C) Conjugated estrogen/medroxyprogesterone (Prempro), 0.625 mg/5 mg orally, once daily
- D) Calcitonin-salmon (Miacalcin) in alternating nostrils daily
- E) A repeat DXA scan in 2 years and initiation of osteoporosis treatment if her FRAX score shows her 10-year risk of major osteoporotic fracture is  $>10\%$

72. A 32-year-old male presents to your office with a right knee injury that occurred while he was playing tennis. His description of the injury indicates that he twisted the knee while his foot was planted. Given the mechanism of injury, you suspect a meniscal tear.

Which one of the following is the most useful single maneuver to evaluate for a meniscal tear?

- A) The anterior drawer test
- B) The pivot-shift test
- C) The valgus stress test
- D) Lachman's maneuver
- E) Thessaly's maneuver

73. An 18-year-old female is seen for a preparticipation physical examination for soccer. She exercises 2–3 hours/day but states that she has low energy levels. Her past medical history includes a stress fracture of the third metatarsal that healed properly. She has intermittent amenorrhea. A physical examination is normal except for a BMI of 18.0 kg/m<sup>2</sup>.

Which one of the following would be most appropriate for this patient?

- A) No further evaluation
- B) An exercise stress test
- C) Echocardiography
- D) Radiographs of both feet
- E) A bone mineral density test

74. A 27-year-old male presents to the emergency department with a 1-week history of fatigue, dyspnea, chest pain, and fever. He is a heroin addict but has no other significant previous history. On examination his lungs are clear but he has a systolic heart murmur. A chest radiograph shows multiple lesions consistent with emboli.

Pending blood culture results, initial antibiotic coverage should include which one of the following?

- A) Clindamycin (Cleocin)
- B) Levofloxacin (Levaquin)
- C) Rifampin (Rifadin)
- D) Trimethoprim/sulfamethoxazole (Bactrim)
- E) Vancomycin (Vancocin)

75. You see a 12-year-old male in October for a preparticipation physical examination for basketball. He has no complaints. You are able to document that he was up-to-date with immunizations at 6 years of age, but has not been vaccinated since. His vital signs and examination are normal.

In addition to Tdap, which one of the following sets of vaccines should be given at this visit?

- A) HPV and varicella
- B) HPV and influenza
- C) HPV, meningococcal, and influenza
- D) Meningococcal, varicella, and influenza



76. A 52-year-old healthy female nonsmoker who has a family history of coronary artery disease presents with episodes of left-sided chest pain that last 10–15 minutes but are unrelated to activity. A resting EKG is normal. She is on medication for hypertension and is in good physical condition.

Which one of the following is the best study to order at this time?

- A) Exercise treadmill testing
- B) Stress echocardiography
- C) Coronary CT angiography
- D) Stress myocardial perfusion imaging
- E) Dobutamine echocardiography

77. A 4-month-old female is brought to your office by her parents because she spits up after most feedings. She is their first child and was born at term with no prenatal or postnatal complications. She is formula fed. A review of her growth chart shows normal growth. Her physical examination and vital signs are normal as well.

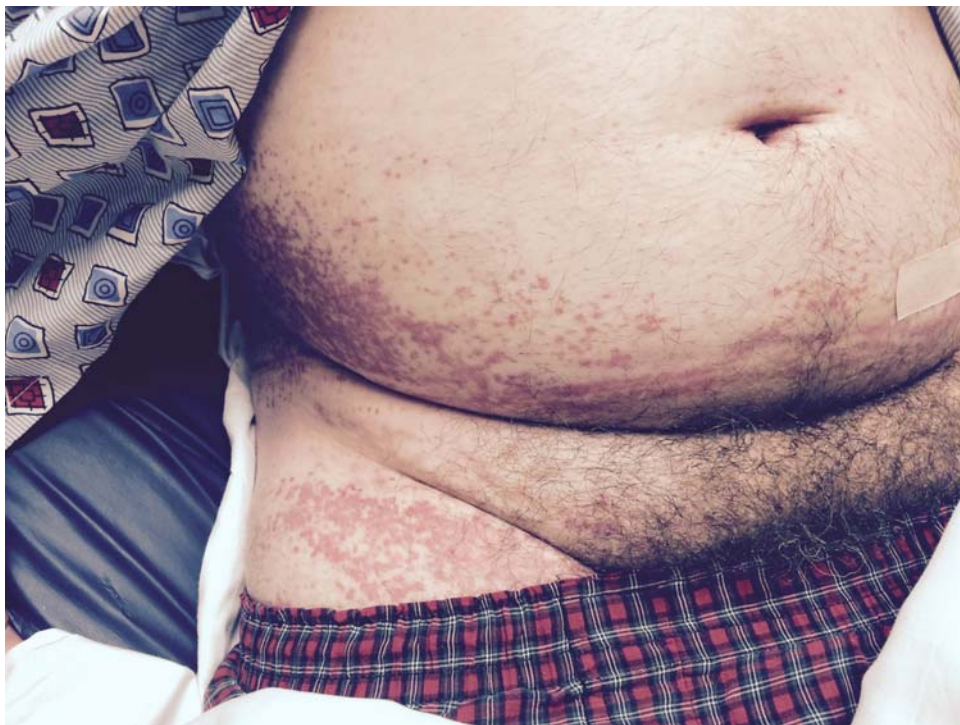Which one of the following would be most appropriate at this point?

- A) Reassurance only
- B) Advising the parents to place the infant in a prone position for sleeping
- C) An upper GI series
- D) Omeprazole (Prilosec)
- E) Ranitidine (Zantac)

78. A 50-year-old male presents to your office with a 4-day history of the rash shown on the page at right. It spread from the lower trunk to the lower extremities, including the genital area. He also complains of pain and swelling of the testes. He considers himself to be in good health and takes no medications. He is afebrile with a normal examination except for the pink-purple maculopapular eruption and bilateral swollen testes. A CBC, urinalysis, and comprehensive metabolic panel are normal.

Which one of the following is the most likely diagnosis?

- A) Henoch-Schönlein purpura
- B) Kawasaki disease
- C) Polyarteritis nodosa
- D) Rocky Mountain spotted fever
- E) Thrombocytopenic purpura



Item #78

79. A 90-year-old male with a history of metastatic lung cancer is admitted to hospice. You agree to follow the patient. The following week the hospice nurse calls you because the patient is complaining of significant dyspnea. His oxygen saturation is 91% on room air. A physical examination reveals diminished but otherwise clear breath sounds.

Which one of the following is the treatment of choice for this patient's dyspnea?

- A) Oxygen
  - B) Albuterol in normal saline by nebulizer
  - C) Prednisone orally
  - D) Morphine sulfate sublingually
  - E) Lorazepam (Ativan) orally
80. A 58-year-old minister comes to your office accompanied by his wife for a follow-up evaluation of personality changes. His wife says he has been making inappropriate comments to females in the church and has been more withdrawn at social gatherings. He has also not been preparing his sermons or balancing their checking account. These behaviors are uncharacteristic for him and his symptoms have been progressively worsening over the past 6–12 months. He is quiet during this discussion. He has been on an SSRI for 3 months with minimal to no improvement. The history is otherwise normal, as is a physical examination, including a focused neurologic examination. Short-term memory is intact.

This presentation is most consistent with which one of the following diagnoses?

- A) Alzheimer's disease
  - B) Frontotemporal dementia
  - C) Lewy body dementia
  - D) Mixed dementia
  - E) Vascular dementia
81. A 54-year-old male returns to your office for follow-up of chronic right knee pain that has worsened over the past month. On examination, range of motion of the knee is normal with no catching in the joint. There is a subtle effusion of the right knee and tenderness along the medial joint line. A radiograph shows medial joint space narrowing and subchondral sclerosis of the medial tibiofemoral joint.

Which one of the following should you recommend at this point?

- A) Stretching and strengthening with physical therapy
- B) Taping and therapeutic ultrasound with physical therapy
- C) Lateral wedge insoles
- D) Oral glucosamine and chondroitin

82. A 5-year-old male has a 10-day history of respiratory symptoms, including nasal congestion. He seemed to improve around day 5 but acutely worsened on day 7 with a new onset of fever, daytime cough, and persistent nasal drainage. On examination his oral temperature is 38.1°C (100.6°F), heart rate 100 beats/min, respiratory rate 24/min, and blood pressure 90/68 mm Hg. He has no sinus tenderness or cervical lymphadenopathy, and normal tympanic membranes bilaterally. You note nasal mucosal swelling and erythema, and mild pharyngeal erythema. Cardiac and lung examinations are normal.

Which one of the following would you recommend?

- A) Saline nasal rinses, decongestants, fluids, and rest
  - B) A laboratory workup including a CBC, an erythrocyte sedimentation rate, and a C-reactive protein level
  - C) Sinus CT
  - D) Amoxicillin
  - E) Azithromycin (Zithromax)
83. According to the JNC 8 panel guidelines, which one of the following would be first-line drug therapy for hypertension in an African-American male who has no other medical problems?
- A) An ACE inhibitor
  - B) An aldosterone antagonist
  - C) An  $\alpha$ -blocker
  - D) Hydralazine
  - E) A thiazide-type diuretic
84. A 13-year-old female has been having difficulty breathing while playing soccer for the last few weeks. She has no personal or family history of asthma and has never needed medical treatments for breathing problems before. Her symptoms include coughing and wheezing only when running intensely for long periods of time. These symptoms persist for up to an hour after she stops exercising. She has no symptoms at other times during the day or at night. A pulmonary function test shows better than average lung function with no change after albuterol (Proventil, Ventolin) inhalation.

Which one of the following treatments would be a good first choice to help with this patient's symptoms?

- A) A 5-day burst of oral prednisone
- B) Daily use of a cromolyn inhaler
- C) Daily inhaled corticosteroids during soccer season
- D) An albuterol inhaler 10–15 minutes prior to exercise
- E) Inhaled salmeterol (Serevent Diskus) every morning during soccer season

85. A 23-year-old male presents with moderate pain and stiffness of the low back and buttock area that began 3–4 months ago. There was no known precipitating event and the symptoms are worsening.

Which one of the following characteristics of his pain and stiffness would make ankylosing spondylitis more likely?

- A) An acute onset over days
- B) Improvement with exercise and activity
- C) Stiffness in the late afternoon and evening
- D) Symptom relief at night

86. In an adult, the radiation exposure from a typical abdominal CT examination is approximately the same as how many posteroanterior chest radiographs?

- A) 4
- B) 40
- C) 400
- D) 4000

87. A 41-year-old male presents to your office for follow-up of recurrent nephrolithiasis. He currently follows a normal diet and does not drink soft drinks very often.

Which one of the following would help prevent recurrent kidney stones?

- A) A loop diuretic
- B) A thiazide diuretic
- C) A high-protein diet
- D) Two 12-oz cola-flavored soft drinks per day

88. You see a 45-year-old white male smoker for follow-up of his hypertension. His past medical history is otherwise unremarkable. At this visit he has a blood pressure of 136/84 mm Hg. A lipid panel reveals the following:

Triglycerides	226 mg/dL
Total cholesterol	228 mg/dL
LDL-cholesterol	159 mg/dL
HDL-cholesterol	31 mg/dL

The ASCVD Risk Estimator yields a 10-year atherosclerotic cardiovascular disease risk of 15.4%.

Based on the 2013 American College of Cardiology/American Heart Association guideline for reducing atherosclerotic cardiovascular disease risk in adults, which one of the following is the most appropriate medication regimen for this patient?

- A) Moderate- or high-intensity statin therapy
  - B) Statin therapy titrated to reduce LDL-cholesterol by 20%–30%
  - C) Combined statin and fibrate therapy to reduce both LDL-cholesterol and triglycerides
  - D) Combined statin and niacin therapy to reduce LDL-cholesterol and raise HDL-cholesterol
  - E) Combined statin and PCSK9 inhibitor therapy to reduce the LDL-cholesterol level to <70 mg/dL
89. Acute altitude sickness consists of headache, nausea, dizziness, and sleep disturbance. Risk factors include which one of the following?
- A) Below-average physical fitness
  - B) Fast ascent
  - C) Age  $\geq$ 65 years
  - D) Male sex
90. A 45-year-old Hispanic female presents to your office for follow-up of a blood pressure measurement of 155/95 mm Hg at a health fair screening. She has no significant past medical history. She reports that she exercises daily for 30 minutes, follows a low-salt diet, and rarely drinks alcohol. Her blood pressure in the office today is 154/95 mm Hg.

Which one of the following medications would be most appropriate for this patient?

- A) Chlorthalidone
- B) Clonidine (Catapres)
- C) Doxazosin (Cardura)
- D) Metoprolol succinate (Toprol-XL)
- E) Spironolactone (Aldactone)

91. A 70-year-old male presents to the emergency department with confusion and a fever of 38.9°C (102.0°F). He has a history of decreased mental status, feeling weak and confused, and low urinary output. On examination he has a blood pressure of 80/50 mm Hg, a pulse rate of 100 beats/min, a respiratory rate of 24/min, and a temperature of 38.9°C (102.0°F). He has mottling of the skin, and his capillary refill time is 5 seconds. A CBC reveals a WBC count of 24,000/mm<sup>3</sup> (N 4500–11,000) with 90% neutrophils. His urinalysis is remarkable for WBCs too numerous to count, with 4+ bacteria. Aggressive intravenous fluid resuscitation and intravenous antibiotics are initiated but the patient remains hypotensive.

Which one of the following would be most appropriate at this point?

- A) High-dose intravenous corticosteroids
  - B) Hydroxyethyl starch (Hespan)
  - C) Low-dose dopamine
  - D) Norepinephrine (Levophed)
  - E) Dobutamine
92. A healthy 65-year-old female presents for a health maintenance visit. She has no record of having received pneumococcal vaccine.

Which one of the following does the CDC recommend for this patient?

- A) Both 13-valent pneumococcal conjugate vaccine (PCV13) and 23-valent pneumococcal polysaccharide vaccine (PPSV23) now
  - B) PCV13 now and PPSV23 in 1 year
  - C) PPSV23 now and PCV13 in 1 year
  - D) Both PCV13 and PPSV23 now, and PPSV23 every 5 years
  - E) PCV13 only, now and every 5 years
93. A 30-year-old male asks about colon cancer screening. He is healthy, but his father was diagnosed with colon cancer at the age of 45.

At what age would you recommend that this patient have his first screening colonoscopy?

- A) 30
  - B) 35
  - C) 40
  - D) 45
  - E) 50
94. Which one of the following is the most common cause of hearing loss in the newborn?
- A) Aminoglycosides
  - B) Genetic inheritance
  - C) Head trauma
  - D) Prematurity
  - E) Rubella

95. A 32-year-old female at 12 weeks gestation presents with an itchy vulvar lesion, which you diagnose as external genital warts. Which one of the following would be accurate advice regarding treatment?
- A) The recurrence rate is low with treatment
  - B) Cryotherapy is the most effective treatment
  - C) Treatment should be based on patient preference
  - D) Treatment is effective in preventing congenital transmission

96. An agitated 35-year-old male is brought to the urgent-care clinic by his wife. She reports that her husband has been restless and tremulous since early this morning. Further history reveals that he was seen 2 days ago for a work-related back injury and was given a prescription for cyclobenzaprine, 10 mg 3 times daily as needed. He reports improvement in his back pain but admits that last night he took an extra dose of a sleeping pill prescribed by his psychiatrist. His chronic medical conditions include controlled essential hypertension and depression.

On examination the patient's vital signs include a temperature of 38.1°C (100.6°F), a blood pressure of 124/82 mm Hg, a heart rate of 98 beats/min, and a respiratory rate of 12/min. The patient appears diaphoretic with a resting symmetrical tremor. He has a regular heart rate and rhythm and his lungs are clear. His abdomen is soft with normal bowel sounds. His strength is 5/5 bilaterally in the upper and lower extremities, and he has 4+ patellar and biceps reflexes bilaterally.

Which one of the following is the most likely explanation for these findings?

- A) Anticholinergic syndrome
  - B) Central cord syndrome
  - C) Malignant hyperthermia
  - D) Neuroleptic malignant syndrome
  - E) Serotonin syndrome
97. A 30-year-old female is 3 months post partum. She had a recent upper respiratory infection and now has anterior neck pain, anxiety, and palpitations. On examination her thyroid is palpable and extremely tender. Laboratory testing reveals that free T<sub>4</sub> is elevated and TSH is suppressed.

Which one of the following is the most likely diagnosis?

- A) Hashimoto thyroiditis
- B) Postpartum thyroiditis
- C) Subacute thyroiditis
- D) Postpartum depression



98. An 82-year-old female with a history of diastolic heart failure, stage 3 chronic kidney disease, and essential hypertension presents to your office with shortness of breath. She does not have chest pain. The physical examination reveals an elderly female in mild distress. Her blood pressure is 138/82 mm Hg, pulse rate 92 beats/min, respiratory rate 24/min, and oxygen saturation 88% on room air, increased to 92% on 2 L/min of oxygen via nasal cannula. Her lungs are clear to auscultation bilaterally. Her heart rate is regular and no murmurs are detected. She has 1+ bilateral lower extremity edema that is slightly worse on the right. A chest radiograph is normal and her D-dimer level is elevated.

Which one of the following would be most appropriate at this point?

- A) A serum BNP level
  - B) A serum troponin I level
  - C) Echocardiography
  - D) A bilateral venous duplex study of the lower extremities
  - E) CT angiography of the chest
99. A 68-year-old female sees you because she developed increased floaters followed by flashes of lights after a sneezing attack. She then noted a dark spot in the periphery of her right eye. Three weeks ago she underwent cataract removal with intraocular lens implantation in this eye. Her examination is notable for decreased visual acuity and a loss of peripheral field in the right eye.

Which one of the following is the most likely diagnosis?

- A) Posterior vitreous detachment
  - B) Central retinal artery occlusion
  - C) Retinal detachment
  - D) Intraocular lens dislocation
  - E) Acute angle-closure glaucoma
100. Which one of the following does the 2014 Global Initiative for Chronic Obstructive Lung Disease (GOLD) guideline recommend for the treatment of exacerbations of COPD?
- A) Prednisone, 40 mg daily for 5 days
  - B) Prednisone, 40 mg daily for 10 days
  - C) A methylprednisolone (Medrol) dose pack
  - D) Methylprednisolone sodium succinate (Solu-Medrol), 100 mg intravenously, followed by prednisone, 40 mg for 7 days
101. When evaluating a patient with menorrhagia, which one of the following laboratory findings would be most consistent with von Willebrand disease?
- A) An isolated prolonged prothrombin time
  - B) An isolated prolonged partial thromboplastin time
  - C) A low serum iron level
  - D) A low platelet count
  - E) A low fibrinogen level

102. A 68-year-old female with well-controlled hypertension presents for a routine evaluation. The physical examination is significant for a BMI of 35.4 kg/m<sup>2</sup>. A comprehensive metabolic panel prior to the visit revealed the following:

Serum calcium . . . . .	9.2 mg/dL (N 8.5–10.2)
Albumin . . . . .	4.0 g/dL (N 3.5–5.4)
Creatinine . . . . .	0.6 mg/dL (N 0.6–1.1)
25-hydroxyvitamin D . . . . .	9 ng/mL (N >20)
Alkaline phosphatase . . . . .	151 U/L (N 47–147)

Which one of the following is true, based on these findings?

- A) She has primary hyperparathyroidism
- B) She should take 1,25-dihydroxyvitamin D (calcitriol)
- C) She should take vitamin D supplements
- D) She should take calcium supplements
- E) She has rickets

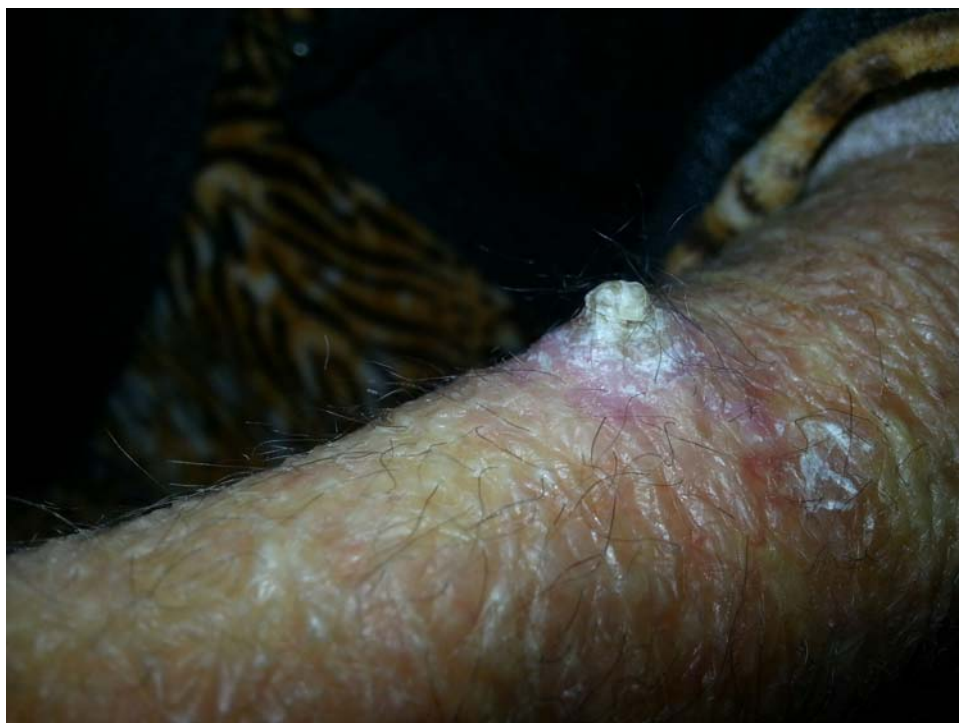103. A 16-year-old male presents with acute testicular pain that has been constant for the last 2 hours. He has nausea and vomiting that started about the same time. On examination you note that the left testis is situated higher in the scrotum than the right testis. The left hemiscrotum is erythematous, slightly warm, and indurated. The patient is currently afebrile.

Which one of the following is the most appropriate management at this time?

- A) NSAIDs and scrotal support
- B) Doxycycline plus intravenous ceftriaxone (Rocephin)
- C) Rotating the testicle from lateral to medial (like closing a book)
- D) Immediate urologic consultation for surgical exploration

104. U.S. federal labor law requires companies with > 50 employees to provide which one of the following benefits for employees who are nursing mothers?

- A) Extended Family and Medical Leave Act protection for a total of 6 months
- B) Reasonable unpaid break time to express milk
- C) Extended bathroom access time to express milk
- D) A refrigerator dedicated to storage of expressed milk



**Item #107**

105. A 30-year-old ICU nurse has been caring for several patients infected with *Clostridium difficile*. She is asymptomatic but is worried that she may also be infected.

Which one of the following is the most appropriate recommendation for this nurse?

- A) No testing and no treatment
- B) Testing for *C. difficile* toxin
- C) Testing for *C. difficile* antigen
- D) Empiric treatment with metronidazole
- E) Probiotics

106. A 36-year-old white male complains of episodic pain in the rectum over the past several years. The pain occurs every 3–6 weeks and is sharp, cramp-like, and severe. It lasts from 1 to 15 minutes. He has no other gastrointestinal complaints. A physical examination, including a digital rectal examination and anoscopy, is normal.

The most likely diagnosis is

- A) fecal impaction
- B) coccygodynia
- C) anal fissure
- D) proctalgia fugax
- E) sacral nerve neuralgia

107. A patient presents with a lesion on her forearm that first appeared 6 months ago. The lesion is shown on the page at left.

Which one of the following is the most likely diagnosis?

- A) A cutaneous horn
- B) Keratoacanthoma
- C) Pyogenic granuloma
- D) Seborrheic keratosis
- E) Verruca vulgaris

108. An 82-year-old female sees you for follow-up 6 weeks after fracturing her hip when she tripped on a hose and fell in her garden. She underwent surgical repair and acute inpatient rehabilitation. She has successfully recovered, is participating in an outpatient physical therapy program, and is now walking with a cane. She reports gastroesophageal reflux controlled with over-the-counter ranitidine (Zantac) as her only chronic medical condition. She recalls having been told that she had only mild bone loss on a bone density test last year. She has been taking a calcium and vitamin D supplement since then. She is concerned about sustaining another fracture.

Which one of the following should you do now to reduce her risk of recurrent fracture?

- A) Prescribe alendronate, 70 mg weekly
- B) Prescribe raloxifene (Evista), 60 mg daily
- C) Prescribe teriparatide (Forteo), 20 µg daily
- D) Discontinue ranitidine

109. A 28-year-old male hospital employee sees you for a mandatory workplace influenza vaccination. He has never received influenza vaccine and is apprehensive about it because of a history of egg allergy. He says he developed hives on his trunk after eating scrambled eggs on several occasions when he was in high school and since then has avoided eating cooked eggs, but not all egg-containing food items. He has had no cases of hives since making this change in his diet.

According to the Advisory Committee on Immunization Practices, which one of the following would be the most appropriate action?

- A) Administer live attenuated influenza vaccine
- B) Administer an intradermal test dose of inactivated influenza vaccine and if the patient does not develop hives administer a full dose of inactivated influenza vaccine 2 or more hours later
- C) Administer inactivated influenza vaccine
- D) Administer oral diphenhydramine (Benadryl) 1 hour before inactivated influenza vaccine
- E) Do not vaccinate for influenza

110. A 65-year-old female presents to your office with a 1-day history of severe low back pain that began acutely after she moved some furniture. She is in good health otherwise, has no previous history of back problems, and has not had a fever. She is having pain in the bilateral low back region, bilateral buttock region, and upper thigh. She has not been able to void since the pain started.

Which one of the following diagnoses should be considered in this patient?

- A) Acute lumbar strain
- B) Lumbar muscle spasm
- C) Mechanical low back pain
- D) Large midline disc herniation
- E) Sciatica

111. A 35-year-old male has a 5-day history of cough and has had one episode of blood-streaked sputum. He is otherwise healthy and has never smoked. He is afebrile and has normal findings on examination. A chest radiograph is normal.

Which one of the following would be most appropriate at this point?

- A) Observation
- B) CT of the chest
- C) Pulmonary function studies
- D) Bronchoscopy
- E) A trial of antibiotics

112. The Timed Up and Go test is used to evaluate geriatric patients for which one of the following?

- A) Risk of falling
- B) Effects of peripheral neuropathy
- C) Kinetic tremor
- D) Neurocardiogenic syncope
- E) Central causes of vertigo

113. Which one of the following can falsely elevate hemoglobin A<sub>1c</sub>?

- A) Antiretroviral treatment for HIV infection
- B) Chronic liver disease
- C) Hemolytic anemia
- D) Iron deficiency anemia
- E) Pregnancy

114. A 62-year-old male presents for a routine health maintenance visit. He has osteoarthritis and controlled hypertension, but is otherwise healthy. He does not smoke and his alcohol consumption consists of 2–3 drinks a week. His medications include lisinopril (Prinivil, Zestril) and acetaminophen. His wife just had a DXA scan and he asks if he should also be screened for osteoporosis.

For this patient, the U.S. Preventive Services Task Force

- A) makes no recommendation for or against DXA
- B) recommends DXA at this visit
- C) recommends DXA at age 65
- D) recommends DXA at age 70

115. A healthy 45-year-old female presents to your office to establish care. She has no significant past medical history and is up to date on her immunizations. She has no chest pain, shortness of breath, or exercise intolerance. She does not take any prescribed medications but does take a low-dose aspirin daily for prevention of coronary artery disease. She does not smoke and she exercises by walking for 45 minutes 4–5 times a week. She is concerned because her mother had a fatal cardiac arrest at age 63 and her father was recently diagnosed with end-stage renal disease at age 75.

On examination the patient's blood pressure is 120/75 mm Hg and her BMI is 22.1 kg/m<sup>2</sup>. Her cardiovascular and pulmonary examinations are unremarkable.

Which one of the following would you recommend to this patient?

- A) A resting EKG
  - B) An exercise EKG
  - C) Discontinuing aspirin therapy
  - D) Increasing aspirin to 325 mg daily
  - E) A basic metabolic panel to screen for chronic kidney disease
116. A 19-year-old female comes to your office with lower abdominal pain that has increased over the past 2 days. Her last menstrual period was 4 days ago. She has been nauseated and has been vomiting. The physical examination reveals a temperature of 38.0°C (100.4°F) and lower abdominal tenderness with mild rebound. She has a mucopurulent cervical discharge, tenderness with cervical motion, a normal-size uterus, and left adnexal fullness. A serum hCG is negative.

Which one of the following is the most appropriate management?

- A) Ceftriaxone (Rocephin), 250 mg intramuscularly
  - B) Hospitalization for intravenous antibiotics
  - C) Surgical consultation for immediate appendectomy
  - D) Laparoscopy
117. An 18-year-old female presents with an intensely pruritic papular eruption in the vicinity of her waist that began shortly after she spent a day walking in the woods with her boyfriend. Her rash consists of multiple small excoriated papules and welts along her beltline. She says she was wearing jeans and sandals.

Which one of the following is the most likely cause of her rash?

- A) Bedbugs
- B) Chiggers
- C) Fleas
- D) Deer ticks
- E) Mosquitoes

118. A homeless 47-year-old male visits the local health department and asks to be screened for tuberculosis. He is not aware of any definite exposure to tuberculosis and is asymptomatic. The nurse asks whether the patient should be screened with a tuberculin skin test or an interferon-gamma release assay (IGRA, QuantiFERON-TB Gold).

Which one of the following would be an advantage of IGRA in this patient?

- A) It helps to distinguish latent tuberculosis from active tuberculosis
  - B) The patient's blood can be stored for up to 36 hours if needed, to allow transport to a qualified laboratory to run the test
  - C) A follow-up visit is not required to obtain results
  - D) The IGRA will be positive within 2 weeks of exposure to an individual with active tuberculosis
  - E) The IGRA can simultaneously detect resistance to rifampin (Rifadin)
119. During a routine health maintenance visit, a 24-year-old female admits that she is not feeling well due to being overwhelmed with stress. She feels she has always worried more than most people, but recent troubles at home and at work have made things much worse. She says she is irritable with people around her, has trouble focusing at work, and feels fatigued late in the day. Despite her fatigue, she has difficulty falling asleep at night. The patient denies anhedonia, suicidal thoughts, or a persistently depressed mood. She limits her caffeine intake, does not smoke or drink alcohol, and is not using any illicit drugs.

In addition to psychotherapy, which one of the following medications is recommended for this patient?

- A) Alprazolam extended release (Xanax XR)
  - B) Clonazepam (Klonopin)
  - C) Gabapentin (Neurontin)
  - D) Quetiapine (Seroquel)
  - E) Sertraline (Zoloft)
120. A 35-year-old female who is approximately 90 kg (200 lb) above her ideal body weight comes to you for weight loss recommendations. Her mother, who had a BMI of 37.0 kg/m<sup>2</sup>, recently suffered a fatal heart attack and the patient would like to avoid this. She has no other medical problems except for well-controlled hypertension. Her medication list includes lisinopril (Prinivil, Zestril), 20 mg daily, and an etonogestrel subdermal (Nexplanon) implant for contraception.

Which one of the following strategies would be most effective for reducing her cardiac risk?

- A) A low-fat diet
- B) A high-protein diet
- C) Orlistat (Xenical), 120 mg 3 times daily with meals
- D) Phentermine (Suprenza), 30 mg daily
- E) Referral for bariatric surgery



121. Which one of the following is most likely to improve outcomes in schizophrenia?
- A) Combining antipsychotic medication with psychosocial treatment
  - B) Prescribing two second-generation antipsychotic medications together in small dosages
  - C) Initial treatment in the outpatient rather than inpatient setting
  - D) Using only one first-generation, or typical, antipsychotic medication combined with an antidepressant medication
122. The preferred method for diagnosing psychogenic nonepileptic seizures (pseudoseizures) is
- A) inducing seizures by suggestion
  - B) postictal prolactin levels
  - C) EEG monitoring
  - D) video-electroencephalography (vEEG) monitoring
  - E) MRI of the brain
123. A 27-year-old male calls and reports that he has an elevated temperature of 101.5°F (38.6°C). He underwent a surgical splenectomy following an automobile accident 5 months ago. He has no allergies and is otherwise healthy.
- Which one of the following would be the most appropriate recommendation for this patient?
- A) Temperature monitoring with follow-up if it exceeds 39.0°C (102.2°F)
  - B) Antipyretics to maintain a temperature < 39.0°C (102.2°F)
  - C) Oral antibiotics, with follow-up if the elevated temperature persists
  - D) Urgent parenteral antibiotic therapy

124. A 4-year-old female is brought to your office with a 6-day history of fever to a maximum temperature of 103.2°F. She was seen 2 days ago and treated empirically for streptococcal pharyngitis because she has a close contact who had a streptococcal infection. She has a mild cough, rhinorrhea, and a sore throat. On examination she is febrile and fussy. She has a maculopapular rash over her trunk, bilateral eye injection, shotty bilateral lymphadenopathy, erythematous lips, a strawberry tongue, and pharyngeal erythema. Her examination is otherwise unremarkable.

#### Laboratory Studies

WBCs	16,200/mm <sup>3</sup> (N 4500–11,000)
Hemoglobin	10.9 g/dL (N 14.0–17.5)
Hematocrit	32.3% (N 41.0–50.0)
Platelets	495,000/mm <sup>3</sup> (N 150,000–350,000)
AST (SGOT)	78 U/L (N 10–30)
ALT (SGPT)	66 U/L (N 10–40)
Alkaline phosphatase	165 U/L (N 30–120)
Albumin	2.8 g/dL (N 3.5–5.5)
C-reactive protein	12.9 mg/L (N 0.08–3.1)
Urine dipstick	normal

A full urinalysis with a microscopic examination reveals 20–25 WBCs/hpf, 0–4 RBCs/hpf, 0–4 bacteria/hpf, and 0–10 epithelial cells/hpf. Additional laboratory tests are ordered, with the following results:

Sodium	132 mEq/L (N 136–142)
Potassium	4.0 mEq/L (N 3.5–5.0)
Chloride	104 mEq/L (N 96–106)
Bicarbonate	22 mEq/L (N 21–28)
BUN	9 mg/dL (N 8–23)
Creatinine	0.6 mg/dL (N 0.6–1.2)

Which one of the following would be the most appropriate management of this patient?

- A) Supportive measures only
- B) Ceftriaxone (Rocephin)
- C) Intramuscular penicillin
- D) Aspirin and intravenous immunoglobulin
- E) Prednisone

125. A 22-year-old male presents to the emergency department with a debilitating headache that occurs 3–4 times per month. Over the past 6 hours he has developed a throbbing, sharp pain over the right side of his head, with significant nausea and vomiting. Previous headaches have not lasted more than 1 day. He did not get any relief with ibuprofen, 600 mg taken 2 hours ago.

Which one of the following is the most appropriate next step in the management of this patient's headache?

- A) Oral acetaminophen
- B) Oral butalbital/aspirin/caffeine (Fiorinal)
- C) Intravenous hydromorphone (Dilaudid)
- D) Intravenous metoclopramide
- E) Supplemental oxygen

126. A 25-year-old female presents to your office to discuss abnormal menstrual periods. She says that her cycles have always been irregular but she has not had any bleeding in 3 months. She also says she has gained 20 lb over the past 6 months. She is not taking any medications. You perform an examination and order laboratory tests. Her blood pressure is 110/72 mm Hg, heart rate 84 beats/min, respiratory rate 12/min, and weight 78.0 kg (172 lb) with a BMI of 29.5 kg/m<sup>2</sup>. She is noted to have moderate cystic acne. Her examination is otherwise unremarkable. A serum hCG measurement is negative and TSH, FSH, and LH levels are normal. Follow-up laboratory evaluation is significant for a total testosterone level 3 times the upper limit of normal and a normal 17-hydroxyprogesterone level.

Which one of the following would be most appropriate at this point?

- A) An estradiol level
- B) A dexamethasone suppression test
- C) Karyotyping
- D) CT of the abdomen and pelvis
- E) MRI of the brain

127. Which one of the following is the most prevalent form of elder abuse?

- A) Financial exploitation
- B) Verbal abuse
- C) Physical abuse
- D) Sexual abuse

128. A 45-year-old female complains of debilitating fatigue that seemed to start suddenly 8 months ago, associated with symptoms of a viral infection. She denies symptoms of depression or substance abuse.

Which one of the following, if present, would indicate a diagnosis other than chronic fatigue syndrome (myalgic encephalomyelitis)?

- A) Impairment of focus and concentration
- B) Joint erythema
- C) Orthostatic intolerance
- D) Post-exertional malaise
- E) Tender lymph nodes

129. A previously healthy 6-month-old female is admitted to the hospital with bronchiolitis. Which one of the following would be an appropriate treatment for this patient?

- A) Albuterol (Proventil, Ventolin)
- B) Epinephrine
- C) Nebulized hypertonic saline
- D) Systemic corticosteroids

130. A 41-year-old premenopausal female presents to your office with amenorrhea, headache, and abnormal vision. Visual field testing reveals bitemporal hemianopsia. You order laboratory tests and MRI of the brain. The MRI reveals a 15-mm mass in the pituitary gland.

Which one of the following laboratory results would suggest an ACTH-secreting adenoma?

- A) Elevated LH and FSH
- B) Elevated serum prolactin
- C) Elevated serum insulin-like growth factor 1
- D) Low free T<sub>4</sub> with a normal TSH level
- E) Elevated 24-hour urine free cortisol

131. The American College of Obstetricians and Gynecologists and the American Academy of Pediatrics support the advance provision of emergency contraception to sexually active women. Evidence shows that this practice

- A) decreases pregnancy rates on a population level
- B) decreases the time from unprotected sex to use of emergency contraception
- C) decreases contraception use by the patient prior to sexual activity
- D) increases rates of sexually transmitted infection
- E) increases rates of unprotected intercourse

132. You see a 90-year-old patient with elevated blood pressure. Which one of the following is an expected physiologic change in elderly patients?

- A) Increased renal blood flow
- B) Increased diastolic blood pressure
- C) Decreased systolic blood pressure
- D) Decreased peripheral resistance
- E) Wider pulse pressure

133. At a routine health maintenance visit a 60-year-old male complains of urinary frequency. A review of systems reveals nocturia but no dysuria. He is otherwise healthy. He has smoked 1 pack of cigarettes per day since age 18 and has a history of benign prostatic hyperplasia (BPH). On examination his prostate is smooth and enlarged without nodules. A dipstick urinalysis shows 1+ blood but is otherwise negative. Urine microscopy reveals 7 RBCs/hpf and 2 WBCs/hpf.

Which one of the following would be most appropriate at this point?

- A) Reassuring the patient that his BPH is causing microscopic hematuria
- B) A repeat urinalysis with microscopy in 6 months
- C) Urine cytology
- D) BUN and creatinine levels, CT urography, and referral for cystoscopy
- E) Empiric antibiotic treatment and a repeat urinalysis after completion of treatment

134. A 32-year-old primigravida at 20 weeks gestation presents with a 5-day history of gradually worsening left calf pain and swelling. She was placed in a walking boot 3 weeks ago to immobilize a left foot fracture. She feels well otherwise, and she specifically denies any chest pain, cough, palpitations, dyspnea, fever, chills, easy bruising, or bleeding. Her examination is notable only for posterior tenderness and swelling of the left calf. A CBC, prothrombin time, and partial thromboplastin time are all normal. Duplex Doppler ultrasonography of the left leg is consistent with deep vein thrombosis.

Which one of the following do you recommend at this point?

- A) Low molecular weight heparin (Lovenox)
- B) Unfractionated heparin
- C) Aspirin and clopidogrel (Plavix)
- D) Rivaroxaban (Xarelto)

135. A 60-year-old male sees you for a follow-up visit for degenerative disc disease that has been causing mild to moderate pain for 6 months. He has had an extensive workup with no reversible or worrisome findings. He has been taking acetaminophen for the past 3 months but remains symptomatic. He asks about herbal supplements that may be beneficial, as he is reluctant to start NSAIDs or opioid therapy at the present time.

Which one of the following supplements has the most evidence of benefit for this problem?

- A) S-adenosyl-L-methionine
- B)  $\alpha$ -Lipoic acid
- C) B-vitamin supplementation
- D) Gamma-linolenic acid (evening primrose oil)
- E) Glucosamine/chondroitin

136. An 86-year-old female is in the emergency department with community-acquired pneumonia confirmed on a chest radiograph. Physical findings include a temperature of 38.4°C (101.1°F), a pulse rate of 101 beats/min, a blood pressure of 101/50 mm Hg, an oxygen saturation of 90% on room air, and a respiratory rate of 32/min. The patient is awake, alert, and oriented times three. The physical examination is otherwise unremarkable except for coarse breath sounds in the left lung base. Laboratory findings include a BUN level of 14 mg/dL (N 8–25), a serum creatinine level of 0.7 mg/dL (N 0.6–1.5), a blood glucose level of 144 mg/dL, and a WBC count of 15,000/mm<sup>3</sup> (N 4300–10,800).

Which one of the following would be most appropriate?

- A) Discharge to home and treatment with azithromycin (Zithromax)
- B) Discharge to home and treatment with amoxicillin/clavulanate (Augmentin)
- C) Discharge to home and treatment with amoxicillin/clavulanate plus azithromycin
- D) Hospital admission and treatment with amoxicillin/clavulanate
- E) Hospital admission and treatment with ceftriaxone (Rocephin) plus azithromycin

137. A 55-year-old female who works at a local day care center presents with a severe cough. Her illness began 10 days ago with malaise, a low-grade fever, rhinorrhea, tearing, and a mild cough. Over the past 3 days the cough has become much more severe and she coughs to the point that vomiting is induced.

Which one of the following is most likely to lead to a definitive diagnosis?

- A) A Gram stain and culture of sputum
- B) Serologic studies
- C) Polymerase chain reaction testing
- D) A chest radiograph
- E) Office pre- and post-bronchodilator spirometry

138. A mother presents to your office with her newborn son for a well child examination. She states that he is healthy and she has no current concerns.

Which one of the following is appropriate in the evaluation of this child for developmental dysplasia of the hip?

- A) Limited hip abduction assessment
- B) Barlow and Ortolani maneuvers
- C) Measurement of leg length
- D) Hip ultrasonography

139. A 6-month-old male is brought to your office for a well child check. He has been healthy except for mild eczema that resolved with about 7 days of a medium-potency corticosteroid when he was 4 months old. He is the only child of a single mother. The mother has introduced some solid foods including eggs, cheese, and bananas, and her son has tolerated these without any trouble. However, she is concerned about introducing peanuts into her son's diet. The mother's brother suffers from a severe peanut allergy and was recently hospitalized after an accidental peanut ingestion. The mother herself does not eat nuts regularly because of her brother's allergy but has had peanuts in small amounts without any trouble.

Which one of the following would you recommend regarding the introduction of foods containing peanuts and other nuts into this child's diet?

- A) Begin introducing these foods before 12 months of age
- B) Start introducing these foods once he has reached 12 months of age
- C) Wait until at least 5 years of age to introduce these foods
- D) Introduce these foods only after allergy testing of the child is performed
- E) Introduce these foods only after allergy testing of the mother is performed

140. Which one of the following is the strongest modifiable risk factor for abdominal aortic aneurysm?

- A) Cigarette smoking
- B) Excessive alcohol consumption
- C) Hyperlipidemia
- D) Hypertension
- E) Type 2 diabetes mellitus

141. Which one of the following antidepressants can prolong the QT interval and should be avoided with concomitant QT-prolonging agents such as atypical antipsychotics?

- A) Bupropion (Wellbutrin)
- B) Citalopram (Celexa)
- C) Mirtazapine (Remeron)
- D) Sertraline (Zoloft)
- E) Venlafaxine

142. A healthy 50-year-old male consults you about preparations for a business trip to India. He will be traveling in rural areas at times and has read that he should have antibiotics with him in case of traveler's diarrhea.

Which one of the following would be best for you to prescribe?

- A) Trimethoprim/sulfamethoxazole (Bactrim)
- B) Azithromycin (Zithromax)
- C) Ciprofloxacin (Cipro)
- D) Rifampin (Rifadin)
- E) Doxycycline

143. A 49-year-old female presents for recheck of an elevated serum calcium level. She complains of constipation and reports that her brother has hypercalcemia. The remainder of her review of systems, physical examination, and past medical, surgical, family, and social histories is unremarkable. She takes no medications.

Six months ago the patient's calcium level was 10.4 mg/dL (N 8.5–10.2) and a serum parathyroid hormone (PTH) level was 58 pg/mL (N 9–77).

Repeat laboratory studies today reveal the following:

Calcium	10.6 mg/dL
Serum PTH	66 pg/mL
24-hour urine calcium	205 mg/24 hour (N 100–300)
Creatinine	0.8 mg/dL (N 0.4–1.1), estimated GFR 62 mL/min/1.73 m <sup>2</sup>
Serum albumin	4.7 g/dL (N 3.2–5.2)
25-hydroxyvitamin D	32 ng/mL (N 30–80)

Which one of the following is the most likely diagnosis?

- A) Familial hypocalciuric hypercalcemia
- B) Primary hyperparathyroidism
- C) Secondary hyperparathyroidism
- D) Secondary vitamin D deficiency
- E) Renal insufficiency

144. You are seated directly across from a patient who has very limited English proficiency. The interpreter you have arranged for enters the examination room and waits next to the door.

In order to best facilitate the interview, you request that the interpreter

- A) maintain her current position by the door
- B) sit next to or slightly behind your patient
- C) sit next to you
- D) stand directly behind you
- E) switch places with you



145. A 6-month-old uncircumcised male is brought to your clinic by his parents, who are concerned because his foreskin remains “tight” and cannot be retracted when they bathe him. He has never been treated for a urinary tract infection or balanitis and his parents report he has a good urine stream. On examination the skin at the preputial outlet appears healthy with no scarring.

Which one of the following is the most appropriate intervention?

- A) Reassurance and continued routine foreskin hygiene
- B) A short course of a topical corticosteroid twice daily to the foreskin
- C) Prophylactic topical antibacterial ointment twice daily
- D) Forceful retraction of the foreskin twice daily to reduce adhesions
- E) Referral to a pediatric urologist for circumcision

146. A 35-year-old female presents to your office with a 3-month history of dyspnea. She does not smoke and has not had a productive cough. She has no other significant past medical history and takes no medications. A chest radiograph reveals significant hilar adenopathy with bilateral infiltrates.

Which one of the following physical examination findings would be consistent with the most likely diagnosis in this patient?

- A) Bilateral conjunctivitis
- B) Alopecia
- C) Erythema nodosum
- D) A malar rash
- E) Xerostomia

147. An 83-year-old male with moderate Alzheimer’s disease and a BMI of 32.6 kg/m<sup>2</sup> is admitted to the nursing home. He has significant osteoarthritis and has difficulty with ambulation. In recent years he has become increasingly frail and has frequently fallen in his home. He has no history of coronary artery disease or stroke, but has had type 2 diabetes mellitus for the past 15 years.

Which one of the following goals would be most appropriate for managing this patient’s diabetes?

- A) A hemoglobin A<sub>1c</sub> of approximately 8%–9%
- B) Limiting caloric intake to 1600 kcal/day
- C) An LDL-cholesterol level < 100 mg/dL
- D) A systolic blood pressure < 130 mm Hg

148. A 66-year-old male is diagnosed with monoclonal gammopathy of undetermined significance. This patient will require regular follow-up visits because of the risk his condition will progress to
- A) aplastic anemia
  - B) multiple myeloma
  - C) chronic lymphocytic leukemia
  - D) acute myelogenous leukemia
  - E) idiopathic thrombocytopenic purpura

149. A 59-year-old female with hypertension takes hydrochlorothiazide and amlodipine (Norvasc). A routine basic metabolic panel is normal except for a mildly elevated calcium level. Upon further questioning, she admits to a history of kidney stones in the past.

After stopping her hydrochlorothiazide, which one of the following laboratory evaluations would be most appropriate?

- A) Parathyroid hormone (PTH) and PTH-related peptide
  - B) 25-hydroxyvitamin D, magnesium, and creatinine
  - C) 24-hour urine calcium and creatinine
  - D) A repeat basic metabolic panel with ionized calcium
  - E) Sestamibi scintigraphy
150. A 10-year-old female is brought to your clinic complaining of toe pain after a playground injury. A radiograph reveals a displaced fracture involving half the joint surface of the first proximal phalanx.

Which one of the following is the most appropriate management of this fracture?

- A) Buddy taping to the second phalanx for 6 weeks
  - B) A rigid-sole shoe for 6 weeks
  - C) A short leg walking cast with a toe plate for 6 weeks
  - D) A posterior splint with orthopedic referral at 1 week
  - E) Prompt orthopedic referral for surgical fixation
151. An 85-year-old female with hypertension and chronic kidney disease was admitted to the hospital for a total knee replacement. The next evening she becomes agitated and disoriented to place and time.

Which one of the following interventions would be most appropriate in this patient's management?

- A) Haloperidol
- B) Zolpidem (Ambien)
- C) Avoiding opioids
- D) Removing hearing aids
- E) Early mobilization

152. You are evaluating a 7-year-old male for long-standing nighttime bed wetting. He has no daytime symptoms and no other health problems. A thorough physical examination is normal.

Which one of the following would be most appropriate at this point?

- A) Urinalysis alone
- B) Urinalysis and a serum metabolic panel
- C) Urinalysis and a lumbosacral radiograph
- D) Urinalysis and renal ultrasonography

153. Which one of the following is the only intervention shown to be effective in the prevention and treatment of pressure ulcers?

- A) Vitamin C supplements
- B) Protein supplements
- C) Topical collagen dressings
- D) Dextranomer paste applied to wounds
- E) Negative-pressure wound therapy

154. A healthy 30-year-old male presents to your office with a 2-cm abscess on his leg. There is no surrounding erythema and he is afebrile. You incise and drain the abscess.

Which one of the following would be the most appropriate management for this patient?

- A) Observation only
- B) Amoxicillin/clavulanate (Augmentin)
- C) Cephalexin (Keflex)
- D) Clindamycin (Cleocin)
- E) Trimethoprim/sulfamethoxazole (Bactrim)

155. Which one of the following is most effective for treating fibromyalgia?

- A) Tricyclic antidepressants
- B) SSRIs
- C) NSAIDs
- D) Opioid analgesics
- E) Corticosteroids

156. An 84-year-old female sees you for a follow-up visit for cardiovascular issues, including a previous myocardial infarction. Her current medication regimen consists of lisinopril (Prinivil, Zestril) and carvedilol (Coreg). While she is not dyspneic at rest, she now becomes short of breath after walking half a block. On examination her blood pressure is 122/74 mm Hg, pulse rate 72 beats/min, respirations 18/min, and oxygen saturation 97% on room air. She has no jugular venous distention and her lungs are clear. No edema is noted. A recent echocardiogram showed a left ventricular ejection fraction of 30%.

Adding which one of the following would help to decrease both mortality and the risk of hospitalization?

- A) Digoxin
  - B) Furosemide
  - C) Isosorbide dinitrate/hydralazine (BiDil)
  - D) Losartan (Cozaar)
  - E) Spironolactone (Aldactone)
157. In a healthy full-term infant who is exclusively breastfed, iron supplementation should begin at what age in order to prevent iron deficiency anemia?
- A) 1 month
  - B) 4 months
  - C) 6 months
  - D) 9 months
  - E) 12 months
158. A previously healthy 46-year-old female presents with a 1-month history of leg swelling and weight gain. She denies chest pain and shortness of breath. She takes no medications, has never smoked, and drinks only an occasional glass of wine.

The physical examination is notable for 2+ pitting edema to the mid-thigh on both legs, and mild ascites. The remainder of her examination is normal. A dipstick urinalysis shows 3+ protein. You suspect primary nephrotic syndrome.

In addition to proteinuria and low albumin, which one of the following is the most common finding in patients with primary nephrotic syndrome?

- A) Coagulopathy
- B) Hypercalcemia
- C) Hyperglycemia
- D) Hyperlipidemia
- E) Infection

159. A 62-year-old male with type 2 diabetes mellitus, hypertension, and hypercholesterolemia is found to have a low serum vitamin B<sub>12</sub> level. Which one of his current medications is most likely to cause this?
- A) Aspirin
  - B) Enalapril (Vasotec)
  - C) Metformin (Glucophage)
  - D) Simvastatin (Zocor)
  - E) Hydrochlorothiazide

160. A 25-year-old gravida 1 para 0 presents for follow-up of gestational diabetes mellitus. She had a positive screening test at her 24-week visit last week and has been checking her blood glucose at home twice daily since that time. She is not currently on any diabetes medications and has a nutrition visit scheduled for later today. She is currently unclear on what her glucose level should be at various times throughout the day.

Which one of the following is the goal fasting blood glucose in this patient?

- A)  $\leq 75$  mg/dL
  - B)  $\leq 95$  mg/dL
  - C)  $\leq 120$  mg/dL
  - D)  $\leq 140$  mg/dL
  - E)  $\leq 180$  mg/dL
161. Which one of the following is the strongest risk factor for primary hypertension in children and adolescents?
- A) A family history of hypertension
  - B) Elevated BMI
  - C) Male sex
  - D) African-American ethnicity

162. A 75-year-old female presents with a 6-week history of the gradual onset of pain behind her right knee. She has a previous history of osteoarthritis and mild hypertension, but no other significant problems. Examination of the knee reveals a soft mass in the medial popliteal fossa that is present when the knee is extended, but is much smaller when the knee is flexed to 45°, which also causes the pain to subside.

Which one of the following would be most appropriate to diagnose this problem?

- A) A plain radiograph
- B) MRI
- C) Ultrasonography
- D) Arteriography
- E) No imaging

163. Which one of the following screening measures does the U.S. Preventive Services Task Force recommend against (USPSTF D recommendation)?

- A) Abdominal ultrasonography to evaluate for an abdominal aortic aneurysm in a 65-year-old male smoker
- B) *BRCA* testing in a high-risk 40-year-old female
- C) A Papanicolaou test in a 58-year-old female who previously had an abdominal hysterectomy for fibroids
- D) Colonoscopy for a 70-year-old male with no history of rectal bleeding

164. A 52-year-old male was admitted to the hospital with evidence of an acute myocardial infarction. He underwent cardiac catheterization and percutaneous coronary intervention with placement of two drug-eluting stents. Echocardiography revealed a left ventricular ejection fraction of 30%. By the time of his discharge the patient had been started on several new medications, including aspirin.

Which one of the following medications is more useful for symptom control than for improving mortality in this situation?

- A) Atorvastatin (Lipitor)
- B) Clopidogrel (Plavix)
- C) Lisinopril (Prinivil, Zestril)
- D) Metoprolol tartrate (Lopressor)
- E) Nitroglycerin

165. A 24-year-old female sees you for follow-up of her chronic abdominal pain. You have diagnosed her with somatization disorder. You have scheduled regular, frequent visits and she has been in counseling for a few months. She still has significant anxiety about her symptoms and you would like to start her on a medication.

Which one of the following medications would be most appropriate for this patient?

- A) Amitriptyline
- B) Aripiprazole (Abilify)
- C) Bupropion (Wellbutrin)
- D) Carbamazepine (Tegretol)
- E) Lamotrigine (Lamictal)

166. A 27-year-old male complains of severe back and left leg pain that started yesterday afternoon. He states that just before the pain began he was moving some patio furniture around his back porch when he felt a sudden “pop” in his left lumbar region. Over the subsequent few hours he developed gradually increasing pain in his low back that radiates down the posterolateral side of his left leg and onto the top of his left foot. He describes the pain as lancinating and knife-like, rating it as 10/10 on a pain scale. He is unable to stand up straight or sit down comfortably for an examination. He denies any bowel or bladder dysfunction and appears to have otherwise intact strength and sensation. Prior to this event he was in good health and took no routine medications.

Which one of the following is recommended at this time?

- A) No imaging
  - B) Radiographs of the lumbar spine only
  - C) CT of the lumbar spine without contrast
  - D) MRI of the lumbar spine without contrast
  - E) MRI of the lumbar spine with contrast
167. The son of a 76-year-old female with metastatic cancer calls you stating that the patient is having uncontrollable nausea. She takes long-acting morphine for pain and he has already tried giving her promethazine and ondansetron (Zofran) without significant benefit. She has been able to drink fluids, but feels “full” and has not eaten more than a few bites of food each day. She has not been vomiting and her urine output has been normal. However, the son reports that she has not had a bowel movement in about 5 days, which he assumes is due to her low intake of food.

Which one of the following would be most appropriate at this point?

- A) Increasing the dosage of oral morphine
  - B) Initiating subcutaneous hydration
  - C) Assessing for possible fecal impaction
  - D) Inserting a nasogastric tube
  - E) Suggesting oral or inhaled marijuana
168. A 90-year-old female is being considered for transcatheter aortic valve replacement due to severely symptomatic critical aortic stenosis. In addition to a medication review, which one of the following tests would be best to assess for frailty as a component of the preoperative assessment?

- A) Gait speed
- B) The Geriatric Depression Scale
- C) The Confusion Assessment Method (CAM)
- D) The Mini-Cognitive Assessment Instrument (Mini-Cog)

169. Which one of the following topical antibiotics used in the treatment of acne vulgaris is not known to increase bacterial resistance?

- A) Benzoyl peroxide
- B) Clindamycin (Cleocin)
- C) Dapsone (Aczone)
- D) Erythromycin
- E) Metronidazole

170. Which one of the following therapies is most likely to reduce abdominal cramping in a patient with irritable bowel syndrome?

- A) Peppermint oil
- B) Polyethylene glycol (MiraLAX)
- C) Probiotics
- D) Wheat bran

171. A 4-year-old male is brought to your office by his neighbor with a 1-day history of fever, lethargy, stiff neck, and rash. You suspect meningitis. The neighbor reports that the patient's father is on his way to the office and should arrive within 30 minutes.

Which one of the following would be most appropriate in this situation?

- A) Initiate treatment now
- B) Obtain informed consent to treat from the neighbor
- C) Call the father to obtain informed consent to treat
- D) Wait until the father arrives to obtain informed consent to treat

172. A 35-year-old female is concerned about a persistent rash on her face. It waxes and wanes in severity but she has persistent redness over her forehead, nose, cheeks, and chin. She also reports an occasional flush that usually lasts less than 5 minutes, sometimes spreads to her neck and chest, and is accompanied by a sensation of warmth. In addition to redness and flushing, the affected areas often contain papules, pustules, and small red streaks. Your examination confirms erythema over her centropacial features with accompanying papulopustular lesions on her nose and telangiectasia on her chin and nose.

Which one of the following agents is an FDA-approved first-line topical therapy for this patient's condition?

- A) Benzoyl peroxide
- B) Clindamycin (Cleocin)
- C) Metronidazole
- D) Selenium sulfide
- E) Tretinoin



173. A 19-year-old female college student is referred to you by her dentist for a medical evaluation related to dental problems. The patient states that she feels well and exercises at least 2–3 hours every day. On examination her teeth are stained and there are enamel erosions. She has nontender enlargement of both parotid glands. The remainder of the examination is normal.

Which one of the following is associated with these findings?

- A) Bacterial parotitis
- B) Bulimia nervosa
- C) Cat scratch disease
- D) Mononucleosis
- E) Mumps

174. A drug available for over 20 years has been noted to have beneficial effects for a common disease. Because it is a cheap, generically available drug, no pharmaceutical firm is willing to fund a clinical trial.

What type of study would be best suited to evaluate this treatment?

- A) A double-blind crossover study
- B) A meta-analysis
- C) A non-inferiority trial
- D) A case-control study
- E) A single-blind trial

175. While working yesterday, a 53-year-old roofer stepped on a nail that went through his shoe and penetrated the sole of his foot. He irrigated his foot thoroughly with water when he got home. He comes to your office today because he has developed some erythema and pain in his foot, with a small amount of drainage.

While *Staphylococcus aureus* and *Streptococcus* species are the most common causes of skin and soft-tissue infection, which organism should also be considered in this situation?

- A) *Corynebacterium*
- B) *Klebsiella*
- C) *Pasteurella multocida*
- D) *Pseudomonas aeruginosa*
- E) *Vibrio vulnificus*

176. A newborn female is found to have constricted ear deformity (cup ears). Her mother had gestational diabetes mellitus.

Which one of the following studies would be most appropriate for this patient?

- A) A single-view chest radiograph
- B) Long bone radiographs
- C) Echocardiography
- D) Renal ultrasonography
- E) Unenhanced head CT

177. The U.S. Preventive Services Task Force recommends routine screening for which one of the following in adolescents?

- A) Alcohol use
- B) Cervical cancer
- C) *Chlamydia* infection
- D) Depression
- E) Scoliosis

178. In an adult patient with significant depression and no other health problems, which one of the following is the best initial choice for pharmacotherapy?

- A) Amitriptyline
- B) Duloxetine (Cymbalta)
- C) Fluoxetine (Prozac)
- D) Mirtazapine (Remeron)
- E) Trazodone (Oleptro)

179. A 29-year-old male presents with a 3-week history of multiple small, brownish-red macules in his left inguinal fold that are now coalescing into larger macules. The rash does not itch, and he has not used any new bath or laundry products. Wood's lamp illumination of the area reveals a reddish fluorescence.

Which one of the following topical treatments would be most appropriate for this patient's rash?

- A) Erythromycin
- B) Hydrocortisone
- C) Nystatin
- D) Selenium sulfide
- E) Zinc oxide

180. Which one of the following is routinely required to establish a diagnosis of chronic lymphocytic leukemia?

- A) A lymph node biopsy
- B) A bone marrow biopsy and aspirate
- C) CT of the chest, abdomen, and pelvis
- D) Flow cytometry and immunophenotyping of peripheral blood
- E) Weight loss of more than 10%, unexplained fever, and night sweats

181. A 43-year-old male presents to your office for an urgent visit because he has a feeling that he is being followed and is fearful for his life. He tells you someone is listening to his cell phone conversations and has stolen files from his laptop, and he has observed “shadowy figures” watching him. He reports that the police have done nothing to protect him, and he has considered hiring a private investigator. He reports that he has been living out of his car for the past month. Upon further questioning the patient admits that he lost his job as an accountant a year ago and is estranged from his family. His overall appearance is unkempt and his speech is pressured and rapid. His heart rate is 88 beats/min, blood pressure 138/80 mm Hg, and temperature 37.0°C (98.6°F).

In ruling out medical causes for his psychosis, which one of the following would be most useful?

- A) The PHQ-9 questionnaire
- B) Urine toxicology
- C) MRI of the brain
- D) HIV antibody testing
- E) A serum calcium level

182. A 62-year-old male with a history of smoking comes to your office for evaluation of a solitary 2-cm right upper lobe pulmonary nodule noted on CT. Which one of the following radiologic features is most predictive of malignancy?

- A) Smooth borders
- B) A ground-glass appearance
- C) Central calcification of the nodule
- D) A solid density

183. A 13-year-old male is brought to the emergency department because of acute worsening of his asthma. His routine medications are inhaled fluticasone (Flovent) and an albuterol metered-dose inhaler (Proventil, Ventolin), which he has used every hour for the past 3 hours without significant improvement. He is unable to talk in complete sentences and his peak expiratory flow is 200 L/min, down from a baseline of 480 L/min. He has no previous history of intubations and only one short hospital admission.

Which one of the following should be given to reduce the likelihood of hospitalization?

- A) Cromolyn
- B) Epinephrine via nebulizer
- C) Inhaled fluticasone
- D) Montelukast (Singulair)
- E) Oral prednisone

184. A 52-year-old gravida 3 para 3 comes to your office with concerns about symptoms related to menopause. Her last menstrual period was 18 months ago. Her main concern is a 1-year history of chronic vaginal dryness, irritation, and painful intercourse. She has occasional mild hot flashes that are minimally bothersome to her. Her obstetric and gynecologic history is unremarkable. On examination you note thin, pale tissue around the introitus, and dry vaginal mucosa.

Which one of the following treatments is safest and most effective for managing her condition?

- A) Oral estradiol (Estrace)
- B) Oral raloxifene (Evista)
- C) Oral conjugated estrogens/medroxyprogesterone (Prempro)
- D) Vaginal estradiol (Estring)
- E) Vaginal etonogestrel/ethinyl estradiol (NuvaRing)

185. A newborn male is brought to your office for his first examination after hospital discharge. He has been diagnosed with Down syndrome.

Which one of the following is indicated for all newborns with Down syndrome?

- A) A cervical spine film
- B) An echocardiogram
- C) Polysomnography
- D) Ultrasonography of both hips

186. One of your patients is admitted to the hospital with an acute myocardial infarction and requires a drug-eluting stent in his left circumflex artery. Which one of the following antiplatelet regimens would be most appropriate for at least the next 6–12 months?
- A) Clopidogrel (Plavix) alone
  - B) Clopidogrel plus aspirin, 81 mg daily
  - C) Aspirin alone, 325 mg daily
  - D) Aspirin/dipyridamole (Aggrenox)
  - E) Prasugrel (Effient) plus aspirin, 325 mg daily

187. In hypothyroid patients, which one of the following makes TSH levels alone unreliable for assessing the response to thyroid replacement?
- A) A history of total surgical thyroidectomy
  - B) Treatment with desiccated thyroid USP
  - C) Treatment with liothyronine (T<sub>3</sub>)
  - D) Hypothyroidism due to pituitary disease
  - E) Graves disease

188. A 65-year-old male is admitted to the hospital with diastolic heart failure and stage 3 chronic kidney disease. He is noted to have a confirmed serum potassium level of 6.8 mEq/L (N 3.6–5.0).

Which one of the following is the best initial management to reduce his potassium level?

- A) Intravenous calcium gluconate solution
  - B) Intravenous furosemide
  - C) Intravenous insulin and glucose
  - D) A rectal sodium polystyrene sulfonate (Kayexalate) retention enema
  - E) Hemodialysis
189. A 2-year-old male is brought to the emergency department by his frightened mother following the sudden onset of nasal stuffiness and a harsh, barking, nonproductive cough. The child does not appear significantly distressed. His temperature is 37.9°C (100.2°F) orally. Mild nasal flaring is present. The nasopharyngeal mucus appears mildly edematous and injected, and upper airway noises are heard, but good air movement is evident on auscultation of his chest.

Which one of the following is the most appropriate treatment for this patient?

- A) A bedside humidifier
- B) A single dose of oral dexamethasone
- C) Amoxicillin for 7 days
- D) Nebulizer treatment with racemic epinephrine
- E) Tracheal intubation and oxygen administration

190. Which one of the following outcomes is seen with intensive glycemic control in patients with type 2 diabetes mellitus?

- A) Fewer hypoglycemic events
- B) Improved blood pressure control
- C) A delay in the development of macroalbuminuria
- D) A reduced need for dialysis
- E) Lower all-cause mortality rates

191. A 61-year-old truck driver is admitted to your service through the emergency department in the evening because of possible cellulitis. When you examine him in the morning he has blistering along his left forearm and dorsal hand that has not receded from the lines drawn in the emergency department. It is not erythematous or tender. He does not recall any injuries, insect bites, infections, or fever, and has been afebrile since admission. He denies pain in his arm, but does complain of itching.

Laboratory studies reveal a normal CBC and comprehensive metabolic panel, with the exception of an ALT (SGPT) level of 100 U/L (N 7–35) and an AST (SGOT) level of 75 U/L (N 10–34). The patient reports no significant past medical problems but has had similar blistering intermittently on the back of both hands that is worse in the summer. He admits to drinking alcohol heavily on the weekends when he is not driving and has smoked a pack of cigarettes per day for the last 45 years.

Which one of the following would be most appropriate at this point?

- A) Intravenous antibiotics until clinical improvement is noted
- B) Discharge on oral antibiotics
- C) Total serum, plasma, or spot urine porphyrins
- D) Ultrasonography of the arm to rule out an underlying abscess
- E) Surgical consultation for possible debridement

192. An 8-year-old male is diagnosed with attention-deficit/hyperactivity disorder. Which one of the following is the most effective treatment?

- A) Behavioral therapy
- B) Atomoxetine (Strattera)
- C) Bupropion (Wellbutrin)
- D) Psychostimulants such as methylphenidate (Ritalin) and dextroamphetamine (Dexedrine)
- E)  $\alpha_2$ -Receptor agonists such as guanfacine (Tenex)

193. A 17-year-old high school football player presents to your office with right fourth finger pain that began suddenly after he made a tackle during last night's game. Pain and tenderness are greatest at the flexor crease of the distal interphalangeal (DIP) joint. He can fully flex the fourth metacarpophalangeal and proximal interphalangeal (PIP) joints. Flexion of the DIP is weak and cannot be held against applied resistance.

Which one of the following is most likely?

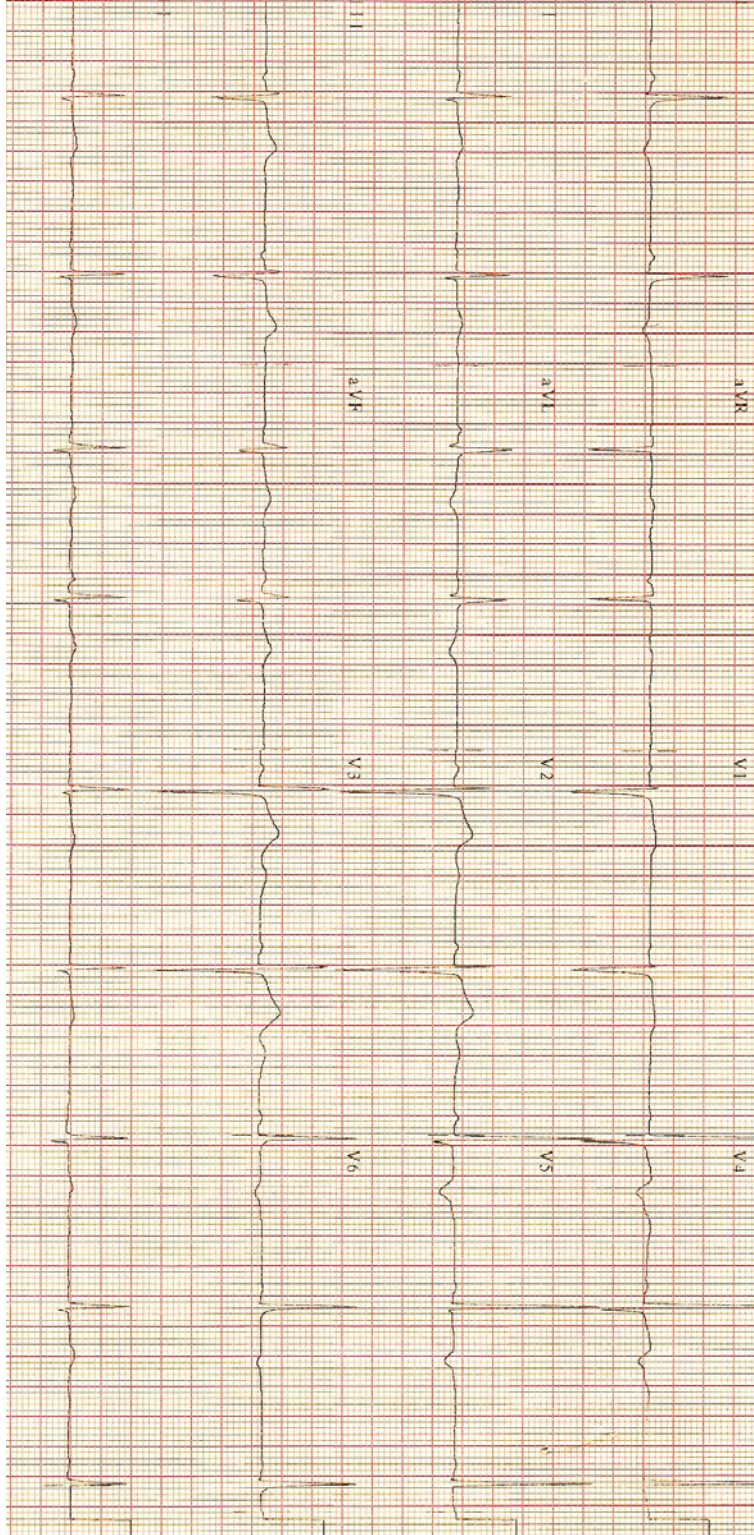
- A) Rupture of the extensor tendon at the DIP
  - B) Rupture of the extensor tendon's central slip at the PIP
  - C) Flexor digitorum profundus rupture
  - D) Rupture of both flexor tendons
194. A 50-year-old female with no other significant past medical history undergoes a total vaginal hysterectomy because of uterine fibroids. She has a pulmonary embolism 2 weeks after the surgery.

How long should she remain on anticoagulant therapy?

- A) 1 month
  - B) 3 months
  - C) 6 months
  - D) 9 months
  - E) Indefinitely
195. Risk factors for sudden infant death syndrome include which one of the following?
- A) Side sleeping
  - B) Being large for gestational age at birth
  - C) A history of an apparent life-threatening event
  - D) Pacifier use
  - E) Asian or Pacific Islander ethnicity
196. An 86-year-old female presents to the emergency department with shortness of breath and a nonproductive cough. On examination she is slightly tachypneic and tachycardic but her temperature and blood pressure are normal. Bilateral crackles are noted on the pulmonary examination, but the cardiac examination is unremarkable. A chest radiograph shows bilateral fluffy infiltrates compatible with heart failure or pneumonia. A CBC, comprehensive metabolic panel, and troponin level are normal. Her EKG shows sinus tachycardia.

Which one of the following laboratory studies would be best to help determine whether the patient should be treated for pneumonia, heart failure, or both?

- A) A serum D-dimer level
- B) BNP and procalcitonin levels
- C) Serial troponin and creatine phosphokinase levels
- D) An erythrocyte sedimentation rate and C-reactive protein level
- E) A serum lactic acid level



Item #197



197. A 52-year-old male runner with a long-standing history of essential hypertension presents for a follow-up visit. A review of his medical record shows blood pressure readings that are consistently 10–15 mm Hg above his goal. He is currently on hydrochlorothiazide, 25 mg/day, and is compliant with a low-sodium diet. An EKG is shown on the page at left.

Based on the EKG, which one of the following would be most appropriate?

- A) A coronary calcium score
  - B) An exercise stress test
  - C) 24-hour Holter monitoring
  - D) Echocardiography
  - E) Coronary angiography
198. A 28-year-old gravida 2 para 1 visits your office for routine prenatal care at 36 weeks gestation. Today she reports some mildly increased lower extremity edema without associated headache, visual changes, or right upper quadrant pain. She has not noticed any leaking amniotic fluid and has only had occasional mild uterine contractions. Her blood pressure has been normal at past visits, but on examination today it is 144/92 mm Hg. Repeat measurement confirms the blood pressure reading, and a urine dipstick shows trace protein. Her fundal height measures 36 cm, fetal heart tones have a rate of 134 beats/min, and Leopold's maneuvers indicate that her fetus is in a cephalic position. Laboratory tests reveal a normal platelet count, normal transaminase and creatinine levels, and a normal urine protein/creatinine ratio.

Your plan at this time should include which one of the following?

- A) Immediate induction of labor
- B) Home blood pressure and symptom monitoring, and induction of labor at 37 weeks gestation
- C) Home blood pressure and symptom monitoring, weekly office visits and laboratory evaluation, and induction of labor at 39 weeks gestation
- D) Home blood pressure and symptom monitoring, weekly office visits and laboratory evaluation, and induction of labor at 40 weeks gestation
- E) Home blood pressure and symptom monitoring, weekly office visits and laboratory evaluation, and induction of labor at 41 weeks gestation

199. A 35-year-old production worker has developed intermittent numbness and paresthesias in the first three fingers of her right hand since being moved to a new workstation 6 weeks ago. These symptoms usually occur mostly while she is working, but sometimes while she is driving or sleeping. She is asymptomatic when you see her in your office. Your examination reveals normal skin color, normal musculature, and no pain to palpation around the hand, wrist, and forearm. Holding the affected wrist in flexion for 30 seconds reproduces her symptoms.

Which one of the following would be most appropriate at this point?

- A) Nerve conduction studies of the hand, wrist, and forearm
- B) Arterial Doppler studies of the hand, wrist, and forearm
- C) A Velcro compression strap to wear just below her right elbow while working
- D) A cock-up wrist splint to wear during times that she is symptomatic
- E) Referral for carpal tunnel release surgery

200. Which one of the following is the preferred first-line treatment for chronic midsubstance Achilles tendinopathy?

- A) Oral NSAIDs
- B) Oral corticosteroids
- C) Local corticosteroid injection of the retrocalcaneal bursa
- D) Eccentric strengthening of the gastrocnemius and soleus muscles
- E) Tendinoplasty

201. A 45-year-old male with hyperlipidemia presents to your office for follow-up. Because of his cardiovascular risk level he has been on moderate-intensity statin therapy with atorvastatin (Lipitor) for the past 6 months. His HDL-cholesterol level at this visit is 29 mg/dL.

Which one of the following steps is most appropriate?

- A) Continue the statin
- B) Add fibrates
- C) Add niacin
- D) Supplement with fish oil

202. A 65-year-old asymptomatic female is found to have extensive sigmoid diverticulosis on screening colonoscopy. She asks whether there are any dietary changes she should make.

In addition to increasing fiber intake, which one of the following would you recommend?

- A) Limiting intake of dairy products
- B) Limiting intake of spicy foods
- C) Limiting intake of wheat flour
- D) Limiting intake of nuts
- E) No dietary limitations

203. A 32-year-old male with type 1 diabetes mellitus presents to your office with a tender, scaly lesion on his anterior left shin. It is a 5-cm reddish-brown plaque with well-defined borders and what appears to be yellowish deposits in the center.

You perform a punch biopsy of the lesion to confirm your diagnosis of

- A) granuloma annulare
  - B) necrobiosis
  - C) sarcoidosis
  - D) xanthoma
204. Pioglitazone (Actos) has been found to be associated with which one of the following adverse effects?

- A) Steatohepatitis
- B) Fluid retention
- C) Cognitive dysfunction
- D) Increased stroke risk
- E) Increased all-cause mortality

205. A 52-year-old male with a history of severe esophageal reflux and dysphagia undergoes upper GI endoscopy that reveals a mid-esophageal stricture and severe erosive esophagitis. The stricture is dilated by the gastroenterologist and he recommends long-term proton pump inhibitor therapy.

While long-term proton pump inhibitor therapy should alleviate symptoms of reflux, it may be associated with an increased risk of which one of the following?

- A) *Clostridium difficile* infection
- B) *Helicobacter pylori* infection
- C) Type 2 diabetes mellitus
- D) Iron deficiency anemia
- E) Hypothyroidism

206. A 4-year-old female is brought to your office after a recent camping excursion and presents with a large number of mosquito bites. She has developed a number of areas of honey-colored crusting lesions you diagnose as nonbullous impetigo.

Which one of the following oral medications is preferred for this patient?

- A) Cephalexin (Keflex)
- B) Doxycycline
- C) Erythromycin
- D) Penicillin VK
- E) Trimethoprim/sulfamethoxazole (Bactrim)

207. Which one of the following medications blocks dopamine stimulation in the chemoreceptor trigger zone, making it an effective antiemetic for patients with gastroenteritis?

- A) Diphenhydramine (Benadryl)
- B) Meclizine (Antivert)
- C) Metoclopramide (Reglan)
- D) Ondansetron (Zofran)
- E) Scopolamine (Transderm Scop)

208. An asymptomatic 46-year-old male with autosomal dominant polycystic kidney disease sees you for a routine visit. His vital signs in the office include a blood pressure of 152/93 mm Hg, a heart rate of 82 beats/min, a respiratory rate of 17/min, a temperature of 37.0°C (98.6°F), and an oxygen saturation of 99% on room air. His glomerular filtration rate is 49 mL/min/1.73 m<sup>2</sup>.

Which one of the following is the preferred initial therapy for controlling this patient's blood pressure?

- A) Amlodipine (Norvasc)
- B) Furosemide
- C) Lisinopril (Prinivil, Zestril)
- D) Metoprolol
- E) Spironolactone (Aldactone)

209. A 70-year-old female presents to your office with a 1-month history of generalized aching of both shoulders. She denies a specific injury but believes that her dog has been pulling too much on the leash. She has also noticed joint stiffness in her hips and trouble getting moving in the mornings. She denies headaches and visual disturbance. A physical examination is normal except for mild pitting edema of the ankles. The patient has lost 5 kg (11 lb) since her health maintenance visit 8 months ago. Laboratory studies reveal an erythrocyte sedimentation rate of 66 mm/hr (N 1–25) and a platelet count of 450,000/mm<sup>3</sup> (N 150,000–350,000). Her creatine kinase level is 50 U/L (N 40–150).

Which one of the following should you prescribe now?

- A) Aspirin, 81 mg daily
- B) Colchicine (Colcrys), 1.2 mg initially, 0.6 mg an hour later, then 0.6 mg daily
- C) Hydroxychloroquine (Plaquenil), 200 mg twice a day for a month then 100 mg twice daily
- D) Methotrexate, 7.5 mg weekly increased by 2.5 mg/week as needed to obtain symptom control
- E) Prednisone, 15 mg daily with a slow taper

210. An active 76-year-old male presents to your office as a new patient. He recently fell while hiking and was diagnosed with rib fractures in the emergency department. He says he has always been healthy except he was told his blood pressure was mildly elevated 10 years ago. He has not followed up with a doctor since that visit. Today his examination is normal other than bruising and mild tenderness over his left 7th to 9th ribs laterally and a blood pressure of 144/88 mm Hg.

You review his transition of care document from the emergency department and his problem list states that he has chronic kidney failure stage 3A based on an estimated glomerular filtration rate of 55 mL/min/1.73 m<sup>2</sup>. A urinalysis in your office is normal, with no hematuria or proteinuria.

Which one of the following would be most appropriate at this time?

- A) Reassurance and observation
  - B) Renal ultrasonography
  - C) CT of the abdomen
  - D) Magnetic resonance angiography of the renal artery
211. A 13-year-old baseball pitcher develops pain in the upper arm at the shoulder when throwing and is diagnosed with Little League shoulder. This entity is actually a
- A) coracoclavicular ligament sprain
  - B) sprain or tear of the acromioclavicular ligament
  - C) deltoid muscle strain
  - D) proximal humeral epiphysitis
  - E) labral tear on the acromion
212. A 35-year-old white male who has had type 1 diabetes mellitus for 20 years begins having episodes of hypoglycemia. His glucose levels had previously been stable and well controlled, and he has not recently changed his diet or insulin regimen.

Which one of the following is the most likely cause of the hypoglycemia?

- A) Spontaneous improvement of  $\beta$ -cell function
- B) Renal disease
- C) Reduced physical activity
- D) Insulin antibodies

213. A 63-year-old female presents with a complaint of a painful, red right eye. She says that her vision has also been blurry. She has also noted a discharge. The patient wears contact lenses.

When you examine the patient you note photophobia. The pupils are equal, round, and reactive to light. You also note unilateral diffuse injection. Fluorescein staining reveals focal corneal uptake.

Which one of the following is the most likely diagnosis?

- A) Corneal abrasion
  - B) Subconjunctival hemorrhage
  - C) Uveitis
  - D) Acute angle-closure glaucoma
  - E) Herpes zoster ophthalmicus
214. A 54-year-old male smoker with a family history of coronary artery disease tells you that he takes  $\beta$ -carotene and vitamin E regularly to help prevent cancer and heart disease. In counseling this patient, you discuss smoking cessation and advise him that
- A) he should continue both supplements
  - B) he should continue  $\beta$ -carotene and discontinue vitamin E
  - C) he should discontinue  $\beta$ -carotene and continue vitamin E
  - D) he should discontinue both supplements
  - E) evidence is insufficient to assess the risk and benefit of these supplements
215. In its dental recommendations from birth to 5 years of age, the U.S. Preventive Services Task Force recommends fluoride supplementation for which one of the following when the primary water supply is deficient in fluoride?
- A) All children starting at birth
  - B) All children starting at 6 months of age
  - C) All children starting at 2 years of age
  - D) All children with erupted primary teeth
  - E) Children with erupted primary teeth who have no access to fluoride varnish
216. You see a 5-week-old female for a well child visit in December. She was delivered at 28 weeks gestation because of severe preeclampsia in the mother. Her parents state that she is doing well, feeding well, and growing. The physical examination is normal.
- At this time, you recommend immunoprophylaxis with
- A) influenza vaccine
  - B) palivizumab (Synagis)
  - C) pertussis vaccine
  - D) rotavirus vaccine
  - E) intravenous immunoglobulin

217. A 25-year-old male presents to the emergency department with a complaint of his heart racing for the past 45 minutes. He has no known medical problems. He does have occasional episodes of palpitations, but they usually only last a short period. An EKG shows a narrow QRS complex tachycardia at a rate of 180 beats/min. His condition is not improved by vagal maneuvers and adenosine (Adenocard). He remains hemodynamically stable.

Which one of the following would be most appropriate at this point?

- A) Amiodarone (Cordarone)
- B) Procainamide
- C) Sotalol (Betapace)
- D) Verapamil (Calan, Verelan)
- E) DC cardioversion

218. A 19-year-old female high school student is brought to your office by a friend who is concerned about the patient cutting herself on the wrists. The patient denies that she was trying to kill herself, and states that she did this because she “just got so angry” at her boyfriend when she caught him sending a text message to another woman. She denies having a depressed mood or anhedonia, and blames her fluctuating mood on everyone who “keeps deserting her,” making her feel like she’s “nothing.” She admits that she has difficulty controlling her anger. Her sleep quality and pattern appear normal, as does her appetite. She denies hallucinations or delusions. The wounds on her wrists appear superficial and there is evidence of previous cutting behavior on her forearms. Her vital signs are stable.

Which one of the following would be most beneficial for this patient?

- A) Clonazepam (Klonopin)
- B) Fluoxetine (Prozac)
- C) Quetiapine (Seroquel)
- D) Inpatient psychiatric admission
- E) Psychotherapy

219. Long-term treatment with which one of the following is known to reduce serum vitamin D levels?

- A) Estrogen replacement
- B) Isoniazid
- C) Phenytoin
- D) Statins
- E) Thiazide diuretics

220. A 6-year-old male is brought to your office by his parents. He describes pain in the right hip for the past month or two, and the parents report that for the past few weeks they have noticed intermittent limping. The history is negative for trauma, injury, and fever. On examination the patient indicates that the pain is over the anterior hip joint, with increased pain on internal rotation, which is limited to 90°.

Of the options listed below, which one of the following is the most likely diagnosis in this case?

- A) Septic arthritis of the hip
  - B) Transient synovitis of the hip
  - C) Osteoarthritis of the hip
  - D) Osteonecrosis of the femoral head (Legg-Calvé-Perthes disease)
  - E) Slipped capital femoral epiphysis
221. Which one of the following is considered first-line therapy for nausea and vomiting of pregnancy?

- A) Ginger
- B) Blue cohosh
- C) Cranberry juice
- D) Vitamin B<sub>6</sub>
- E) Fenugreek

222. A 38-year-old female calls your office and reports nausea, vomiting, abdominal cramps, and diarrhea that developed 1 hour after she ate some chicken salad that had been sitting outside at a picnic. Prior to that she was asymptomatic.

Which one of the following is the most likely cause of this patient's foodborne illness?

- A) *Campylobacter jejuni*
- B) *Escherichia coli* O157:H7
- C) *Shigella* species
- D) *Staphylococcus aureus*
- E) Hepatitis A

223. A 76-year-old nursing home resident complains of constipation. He has had minimal improvement with trials of scheduled toileting and increased fiber and fluids. A physical examination is normal.

Which one of the following is the best intervention at this point?

- A) Bisacodyl (Dulcolax)
- B) Lactulose solution
- C) Magnesium citrate solution
- D) Polyethylene glycol (MiraLAX)



224. A 44-year-old male complains of feeling tired and sad for the last few months. He has a past medical history of obesity, diabetes mellitus with painful peripheral neuropathy, and seizure disorder. He has also noticed that he is not as interested in his usual hobbies and is eating more than usual. You diagnose depression.

Which one of the following would be the most appropriate agent for this patient, considering his comorbidities and symptoms?

- A) Bupropion (Wellbutrin)
- B) Citalopram (Celexa)
- C) Duloxetine (Cymbalta)
- D) Nortriptyline (Pamelor)

225. A 16-year-old male presents to your office with a 1-month history of paresthesias in the ring finger and little finger of his left hand. He is the catcher on his high school baseball team. The physical examination reveals no abnormalities of his neck, shoulder, or elbow. His hand grip is normal, but maximal flexion of the wrist elicits paresthesias in the fourth and fifth digits.

Which one of the following is the most likely diagnosis?

- A) Carpal tunnel syndrome
- B) Ulnar entrapment
- C) Flexor carpi ulnaris tendinitis
- D) De Quervain's tenosynovitis
- E) Stress fracture of the scaphoid

226. A 52-year-old male was recently diagnosed with mild essential hypertension. His average blood pressure over several repeated weekly readings is 142/92 mm Hg. He now comes to your office to discuss a management plan. He is particularly interested in trying to manage his hypertension nonpharmacologically if possible.

Which one of the following nonpharmacologic interventions should you recommend for this patient?

- A) Limit table salt consumption to 500 mg/day
- B) Consume 3 glasses of red wine daily
- C) Consume a high-protein diet
- D) Monitor home blood pressure readings
- E) Start a yoga program

227. A 52-year-old male sees you at the request of his wife because of his snoring and her concerns that he has obstructive sleep apnea. Further evaluation with a sleep study is recommended if the patient reports which one of the following?
- A) Insomnia
  - B) A history of hypertension
  - C) Snoring that awakens his wife
  - D) Unexplained daytime sleepiness
228. A healthy 18-year-old male plans to play soccer and basketball and presents for a preparticipation sports evaluation. The American Academy of Family Physicians recommends AGAINST which one of the following measures to screen for cardiac disease for this patient?
- A) A detailed past medical history
  - B) A detailed family history
  - C) A detailed cardiovascular physical examination
  - D) An EKG
229. A full-term newborn female develops respiratory distress 1 hour after an uncomplicated caesarean delivery. She has a respiratory rate of 70/min, and mild grunting and intercostal retractions are noted on examination. The remainder of the examination is within normal limits. A chest radiograph shows some hyperexpansion and fluid in the fissures.
- Which one of the following is the most likely cause of her symptoms?
- A) Respiratory distress syndrome of the newborn
  - B) Transient tachypnea of the newborn
  - C) Pneumothorax
  - D) Meconium aspiration syndrome
230. In a critically ill adult, which one of the following options for deep vein thrombosis prophylaxis is associated with the greatest reduction in mortality risk?
- A) Anticoagulation therapy
  - B) Antiplatelet therapy
  - C) Mechanical device use (pneumatic compression)
  - D) Inferior vena cava filter use

231. An 18-year-old male comes to your office because of the recent onset of recurrent, unpredictable episodes of palpitations, sweating, dyspnea, gastrointestinal distress, dizziness, and paresthesias. He says he is always concerned about when the next attack will occur. His physical examination is unremarkable except for moderate obesity. Laboratory findings, including a CBC, blood chemistry profile, and TSH level, reveal no abnormalities.

The most likely diagnosis is

- A) mitral valve prolapse
  - B) paroxysmal supraventricular tachycardia
  - C) pheochromocytoma
  - D) generalized anxiety disorder
  - E) panic disorder
232. A 70-year-old male comes to your office for a wellness evaluation. He smoked for many years, but quit 10 years ago. While searching through several health-related websites he read that because of his smoking history he should undergo screening for an abdominal aortic aneurysm.

Which one of the following screening tests for abdominal aortic aneurysm is recommended by the U.S. Preventive Services Task Force for this patient?

- A) One-time low-dose abdominal CT
  - B) One-time diffusion-weighted MRI
  - C) One-time conventional abdominal duplex ultrasonography
  - D) Annual conventional abdominal duplex ultrasonography
  - E) No screening tests
233. A 35-year-old female presents to your office with a 2-week history of pain, mild swelling, and point tenderness in the midportion of her anterior tibia. She has recently increased her jogging from 6 miles per week to 30 miles per week. She is unable to hop on the involved leg, as this induces significant pain at the site. A plain radiograph reveals a faint lucency at the same location.

This patient would most likely benefit from which one of the following?

- A) NSAIDs
- B) Bisphosphonate therapy
- C) Vitamin E supplementation
- D) A bone stimulator
- E) A walker boot

234. A 42-year-old female continues to have elevated blood pressure while on three antihypertensive agents. You are concerned that she may have idiopathic adrenal hyperplasia or an aldosterone-producing adenoma.

Which one of the following would be the most appropriate laboratory test?

- A) Serum cortisol
- B) An aldosterone:renin ratio
- C) 17-Hydroxyprogesterone
- D) A dexamethasone suppression test
- E) Renal ultrasonography

235. For the past 2 weeks a 16-year-old female has had an eruption on one breast, shown below. She reports being troubled by the appearance of the lesions.

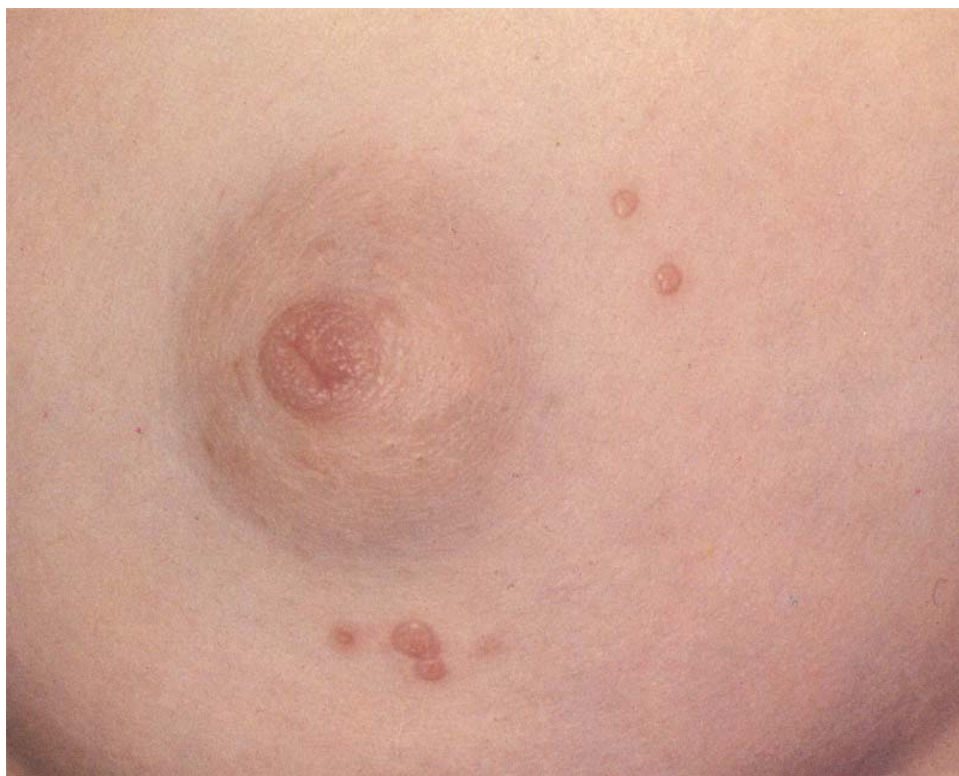Of the following, the most appropriate management of this condition is to

- A) curette each lesion to remove the top
- B) apply a corticosteroid ointment locally twice daily for 10 days
- C) advise the patient that the lesions will disappear in 2 weeks without treatment
- D) prescribe penicillin, once daily for 10 days
- E) order a serologic test for syphilis and treat if positive

236. A 45-year-old male presents with what he suspects is a dislocated finger. He was playing football with some friends 2 days ago and when he was trying to catch the ball it struck his finger. On examination the distal interphalangeal (DIP) joint of the left fifth finger has full passive range of motion, but he cannot actively extend the joint. A radiograph confirms an avulsion fracture from the dorsum of the proximal fifth distal phalanx, with a mallet deformity.

Which one of the following is the most appropriate treatment of this fracture?

- A) Immobilization of the DIP joint in 30° flexion for 6–8 weeks
- B) Immobilization of the DIP joint in extension for 6–8 weeks
- C) Immobilization of both the DIP and proximal interphalangeal (PIP) joints in extension for 6–8 weeks
- D) Referral for surgical pinning



**Item #235**

**237.** A 62-year-old male with severe COPD without hypoxia (based on spirometry within the last year) comes to your office because of continued breathlessness. He has a 41-pack-year smoking history but stopped 1 year ago and reports he is using his inhalers as prescribed, which include albuterol (Proventil, Ventolin) as needed, budesonide/formoterol (Symbicort) twice daily, and tiotropium (Spiriva) daily. He has previously demonstrated that he is able to use the metered-dose inhalers appropriately. He is discouraged about his continued difficulty breathing and asks if there is anything else that can be done to improve this problem. His oxygen saturation on room air in the office is 92%.

Which one of the following would be most appropriate at this time?

- A) Replace his inhaled medications with nebulized alternatives
- B) Replace his tiotropium with ipratropium (Atrovent)
- C) Order home oxygen
- D) Refer for outpatient pulmonary rehabilitation

**238.** A 68-year-old female who is a recent immigrant from Mexico is brought to your office by her son with a complaint of headaches. The patient speaks English adequately, but diverts her eyes to look at her son when answering your questions.

Which one of the following is the most likely reason for this patient not making eye contact?

- A) Her son is overly controlling
- B) She is a victim of abuse
- C) She is being untruthful
- D) She is showing respect to you
- E) She is depressed

**239.** Which one of the following is an absolute contraindication to combined oral contraceptives in a 42-year-old female?

- A) Varicose veins
- B) Obesity (BMI > 30.0 kg/m<sup>2</sup>)
- C) Sickle cell disease
- D) A history of ovarian cancer
- E) Smoking 1 pack of cigarettes/day

**240.** Which one of the following descriptions of an injury by an athlete is most consistent with an isolated posterior cruciate ligament tear?

- A) Hearing a pop in the knee during a pivoting motion
- B) An immediate onset of pain after cutting on the knee
- C) A direct blow to the anterior tibia while the knee is in flexion
- D) Forceful twisting of the knee
- E) An onset of pain after a running jump